

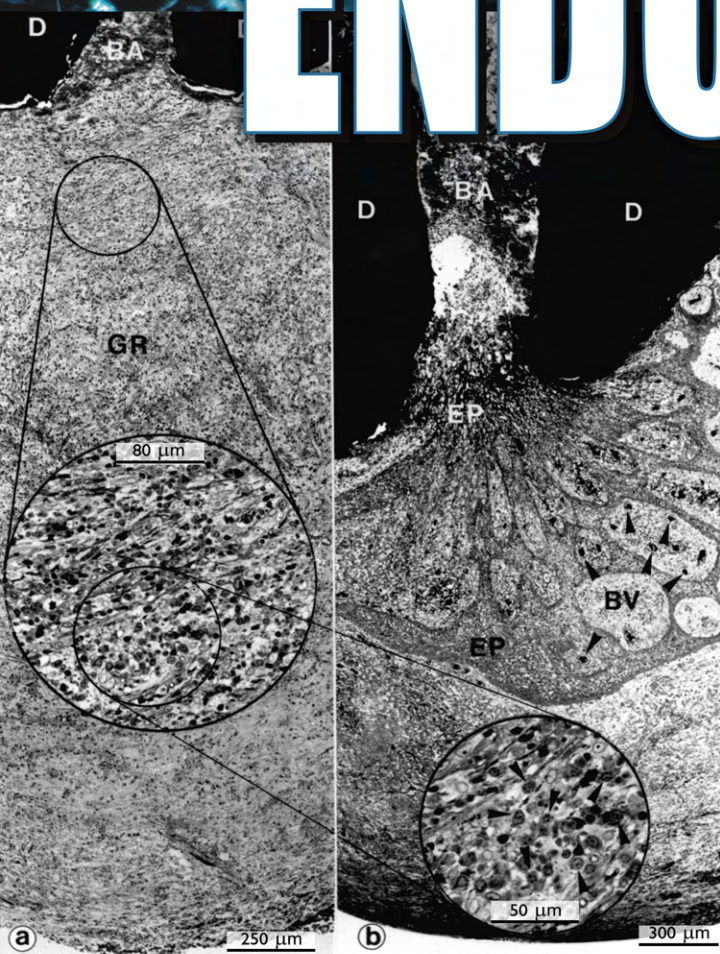
# TEXTBOOK

*of*

# ENDODONTICS

*Edited by*

**Anil Kohli**





# TEXTBOOK *of* ENDODONTICS

*Edited by*

**Anil Kohli**

BDS, MDS (Lko), FDS, RCS (Eng) DLit (Honoris Causa), DSc

Endodontist and Dental Surgeon

President, Dental Council of India, New Delhi

Dean, Faculty of Dentistry, Baba Farid University, Punjab

Adjunct Professor, Boston and Tufts University

Fellow, Royal College of Dental Surgeons of England

Chairman, Education Committee, Asia Pacific Dental Congress (APDC)

Member, Education Committee, Fédération Dentaire Internationale (FDI)



**ELSEVIER**

*A division of*

Reed Elsevier India Pvt Ltd.

***Dedicated to***

*My children—Malika, Sonali, Mohit,  
and my beloved wife Sushma.*

***Anil Kohli***

*Dr M Velayutham, my Father for showing what integrity and principles are....  
Dr E Munirathnam Naidu, my Mentor, for being a role model who walks his talk....  
Dr K Sridhar; my Godfather, and an all-weather friend and counsellor.....*

***V Gopikrishna***



# List of Contributors

**Anil Kohli**, MDS, FDS RCS (Edin), DLit  
(Honoris Causa), DSc  
President , Dental Council of India  
Chairman of Commission for Education, Asia-Pacific  
and Commonwealth Countries

**Gopikrishna V**, MDS, FISDR  
Editor in Chief, Journal of Conservative Dentistry  
Associate Professor, Dept Dentistry and Endodontics  
Meenakshi Ammal Dental College  
Chennai, India

**James L Gutmann**, DDS, PHD (Honoris Causa), Cert  
Endo, FACD, FICD, FADI  
Former Professor of Endodontics and  
Restorative Sciences  
Baylor College of Dentistry  
Texas A&M University System  
Dallas, Texas, USA

**Nair PNR**, BVSc, DVM, PhD (Honoris Causa)  
Senior Scientist  
Institute of Oral Biology  
Centre of Dental and Oral Medicine  
University of Zurich  
Zurich, Switzerland

**Syngcuk Kim**, DDS, PhD, MD (Hon)  
Louis I Grossman Professor and Chairman  
Dept of Endodontics  
University of Pennsylvania  
Philadelphia, Pennsylvania, USA

**Meetu Ralli Kohli**, DMD  
Dept of Endodontics  
University of Pennsylvania  
Philadelphia, Pennsylvania, USA

**Anil Kishen** BDS, MDS, PhD  
Associate Professor, Discipline of Endodontics  
Dept of Clinical Sciences  
Faculty of Dentistry, University of Toronto  
Toronto, Canada

**Andreas Moritz** MD, DMD  
President der ESOLA  
Vienna, Austria

**Sivapathasundharam B**, MDS  
Professor and Head  
Dept of Oral Pathology  
Meenakshi Ammal Dental College  
Chennai, India

**Suresh Chandra B**, MDS  
Principal, AJ Institute of Dental Sciences  
Kuntikana, Mangalore

**Lakshmi Narayanan L**, MDS  
Dean, SRM Kattankulathur Dental College and  
Hospital  
SRM University  
Kancheepuram, Tamil Nadu

**Carounanidy Usha**, MDS  
Professor and Head  
Dept of Dentistry  
Pondicherry Institute of Medical Sciences  
Kalapet, Pondicherry, India

**Suresh R**, MDS, PhD  
Dean, Sri Ramachandra Dental College  
Sri Ramachandra University  
Chennai, India

**Kundabala M**, MDS  
Professor and Head  
Dept of Conservative Dentistry and Endodontics  
MCODS, Mangalore, India

**Vivek Hegde**, MDS  
Professor and Head  
Dept of Conservative Dentistry and Endodontics  
Rangoonwala Dental College  
Pune, India

**Siju Jacob**, MDS  
Root Canal Clinic  
Bangalore, India

**Suma Ballal**, MDS  
Professor  
Dept of Conservative Dentistry and Endodontics  
Meenakshi Ammal Dental College  
Chennai, India

**Sanjay Miglani, MDS**

Associate Professor

Dept of Conservative Dentistry and Endodontics

Faculty of Dentistry

Jamia Millia Islamia (a Central University)

New Delhi

**Krithika Datta, MDS**

Senior Lecturer

Dept of Conservative Dentistry and Endodontics

Meenakshi Ammal Dental College

Chennai, India

**Sunitha Raja, MDS**

Senior Lecturer

Dept of Periodontics

Meenakshi Ammal Dental College

Chennai, India

**Abarajithan, MDS**

Senior Lecturer

Dept of Conservative Dentistry and Endodontics

Meenakshi Ammal Dental College

Chennai, India

**Majumdar D, MDS**

Principal R. Ahmed Dental College

Kolkata, India

# Preface

The discipline of endodontics has evolved rapidly over the years, both in terms of our understanding of the pathobiology of the disease process as well as in the evolution of chemo-mechanical means in the management of the pulp space. The genesis of this textbook was to cater to the lacunae existing in the Indian undergraduate textbooks, which were either outdated or were of postgraduate standards.

Keeping this as our mission objective, I endeavoured to bring about a textbook that would encompass and cater to the specific needs of our students. Many eminent national and international personalities, who excel in the art and science of endodontics, have made their contributions to this book. The presentation of the text has been kept in a simple, lucid, and reader-friendly manner with many clinical pictures and illustrations.

This book has been completely updated to include the most current techniques and materials developed for the management of pulp and periapical tissues.

**Anil Kohli**

# Acknowledgements

This textbook is a tribute to all my teachers, students, friends, and disciples in the field of endodontics. It has always been my dream to write a book of truly international standards and calibre, which would serve as the ideal medium of information and reference for a student to learn and practice the art and science of endodontics.

I, along with my team of contributors, have taken close to 2 years in conceiving and executing this project to perfection. I would like to acknowledge each one of my contributors for their excellent commitment and academic zeal to share their knowledge with us. I would like to acknowledge my international contributors James L Gutmann, PNR Nair, Meetu Ralli Kohli, Syngcuk Kim, Andreas Moritz, and Anil Kishen for their wonderful contributions to this endeavour of mine. A galaxy of nationally acclaimed academicians including B Sivapathasundharam, B Sureshchandra, Carounanidy Usha, L Lakshminarayanan, D Majumdar, M Kundabala, and R Suresh have made significant contributions in enriching this book.

A special word of praise and appreciation for my chief contributor, V Gopikrishna for assisting me in this book right from the inception. He along with a team of young and dynamic academicians like Vivek Hegde, Siju Jacob, Suma Ballal, Sanjay Miglani, Krithika Datta, and Abarajithan have been instrumental in making my endeavour successful. Special thanks to Drs Vishal and Nidhi Gupta for being there with me at every stage of the book.

Finally, I would like to thank Elsevier for their professional expertise in making this book a reality. I would like to thank the Lord Almighty, my parents, my teachers, my wife, and my wonderful daughters for being the inspiration and motivation, and giving me all the moral support.

**Anil Kohli**

The motivation to write a textbook for the undergraduate students of India came from the observation that in spite of a plethora of textbooks, there is not a single truly updated textbook for a final year BDS student. A book of this magnitude and scope can never be accomplished by a single individual, and is the outcome of the tremendous efforts of numerous individuals. This book is a true team effort.

I would like to first thank the Spirit of Nature and God for giving me the intellect, fortitude, and perseverance to accomplish this task. My sincere thanks to the Editor and the President, Dental Council of India, *Padmabhushan* Dr Anil Kohli for giving me the opportunity, encouragement, and freedom to be involved in every stage of this book.

My sincere thanks to each one of the contributors for their intellectual excellence. They are the true heart and spirit of this textbook. A special word of gratitude and thanks to Dr PNR Nair, Dr James 'Jim' Gutmann, and Dr B Sivapathasundharam for constructively guiding me in this endeavour. I have been blessed to have wonderful teachers who have moulded me and my sincere gratitude to Dr A Parameswaran, Dr B Suresh Chandra, Dr D Kandaswamy, and Dr L Lakshminarayanan.

A team of well wishers, friends, and students have helped me in every stage of this book. A heartfelt gratitude to Dr P Jayakumar, Dr Ambalavanan, Dr Meera, Dr Abarajithan, Dr Krithika Datta, Dr Venkatesh Babu, Dr Galli Padeep, Dr Vijayalakshmi, Dr Smita Surendran, Dr Santosh, Dr Sonal, Dr Anuradha, Dr Anuj, Dr Denzil, Dr Saveetha Seshadri, Dr Anusha, and Dr Krishnamurthi.

I would like to place on record the excellent support we received from team Elsevier. Thank you Ms Ritu Sharma and Mr Anand K Jha for your professionalism and patience with me.

Finally, I thank my wife Lakshmi, children Sanjana and Sidharth, my mother Sulochana, and my father Velayutham, for being understanding and supportive during my hibernation for this project.

**V Gopikrishna**

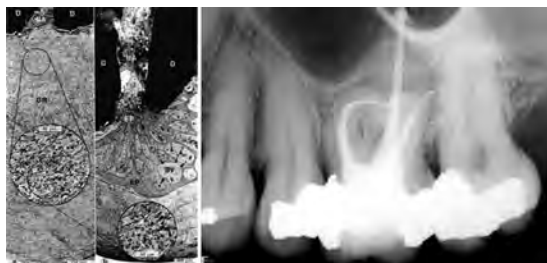
# Contents

<i>Dedication</i> .....	<b>v</b>
<i>Foreword</i> .....	<b>vii</b>
<i>List of Contributors</i> .....	<b>ix</b>
<i>Preface</i> .....	<b>xi</b>
<i>Acknowledgements</i> .....	<b>xiii</b>
<b>Chapter 1    Introduction and Scope of Endodontics</b> .....	<b>1</b>
• Definition of endodontology and endodontics • Brief introduction to pulpal / periapical disease	
<b>Chapter 2    Dental Pulp</b> .....	<b>3</b>
• Introduction • Anatomy of the pulp • Development • Histologic features • Cells of the pulp	
• Pulp core • Functions of the pulp • Ageing pulp • Clinical considerations • Bibliography	
<b>Chapter 3    Rationale of Endodontic Treatment</b> .....	<b>14</b>
• Pulpal and periradicular reactions to stimuli • Inflammation • Vascular changes • Periradicular manifestations • Endodontic implications • Bibliography	
<b>Chapter 4    Diagnosis</b> .....	<b>22</b>
• Introduction • Visual and tactile inspection • Vascular supply • Transmitted-light photoplethysmography • Laser Doppler flowmetry • Pulse oximeter • Bibliography	
<b>Chapter 5    Microbiology in Endodontics</b> .....	<b>37</b>
• Introduction • History of association between microbes and endodontic disease • Pathways of pulpal infection • Microorganisms associated with pulpal and periradicular diseases • Prevalent species associated with symptomatic (associated with pain) periradicular lesions • Other microorganisms causing endodontic diseases • Detection and identification of endodontic pathogens • Bibliography	
<b>Chapter 6    Isolation and Infection Control in Endodontics</b> .....	<b>49</b>
• Isolation In endodontics • Infection control in endodontics • Bibliography	
<b>Chapter 7    Diseases of the Pulp</b> .....	<b>63</b>
• Introduction • Causes of pulp diseases • Diseases of the pulp • Bibliography	
<b>Chapter 8    Pathobiology of Apical Periodontitis</b> .....	<b>82</b>
• Introduction • Classification of apical periodontitis • Primary apical periodontitis • Host defence	
• Molecular mediators • Effector molecules • Pathogenesis • Persistent apical radiolucencies (endodontic failures) • Microbial causes • Non-microbial causes • Summary • Bibliography	
<b>Chapter 9    Root Canal Morphology and Access Preparation</b> .....	<b>125</b>
• Introduction • Components of root canal system • Guidelines to access cavity preparation in permanent teeth • Basic outline shapes of access cavity preparation in permanent teeth • Bibliography	
<b>Chapter 10    Dental Radiology</b> .....	<b>134</b>
• Introduction • Types of radiographs • Various radiographic techniques • Reduction against radiation • Frequently asked questions • Digital radiographs • Bibliography	



<b>Chapter 11</b>	<b>Working Length Determination</b>	<b>144</b>
	• Introduction • Definitions • Cemento-dentinal junction • Significance of working length • Stop attachments • Different methods of working length determination • Ideal method • Radiographic methods of working length determination • Non-radiographic methods • Electronic apex locators • Summary • Bibliography	
<b>Chapter 12</b>	<b>Cleaning and Shaping of Root Canal System</b>	<b>154</b>
	• Introduction • Principles of shaping root canal system • Instruments for cleaning and shaping • Standardization of instruments • Basic motions of instrumentation • Techniques of instrumentation • Clinical significance • Irrigants • Ideal requirements of a root canal irrigant • Types of root canal irrigants • Bibliography	
<b>Chapter 13</b>	<b>Intracanal Medicament</b>	<b>174</b>
	• Introduction • Antimicrobial effectiveness • Intracanal medicaments • Calcium hydroxide • Summary • Bibliography	
<b>Chapter 14</b>	<b>Obturation of the Root Canal System</b>	<b>184</b>
	• Introduction • Sealers • Root canal obturating techniques—advantages and disadvantages • Lateral compaction of cold gutta-percha • Multiple point obturation with lateral compaction • Variations of lateral compaction • Bibliography	
<b>Chapter 15</b>	<b>Pulpotomy and Apexification</b>	<b>209</b>
	• Introduction • Pulpotomy • Apexification • Summary • Bibliography	
<b>Chapter 16</b>	<b>Traumatic Injuries</b>	<b>232</b>
	• Introduction • Classification • Examination • Chief complaint • Crown-root fractures • Root fracture • Vertical root fracture • Luxation injuries • sequelae of attachment damage and pulp necrosis • Prognosis of pulp after luxation injuries • Avulsion • Bibliography	
<b>Chapter 17</b>	<b>Endodontic Microsurgery</b>	<b>250</b>
	• Introduction • Traditional versus microsurgical techniques • Objectives of surgery • Rationale for surgery • Indications • Contraindications • Classification of microsurgical cases • Clinical procedure • Apical management • Treatment outcome • Intentional reimplantation • Summary • Bibliography	
<b>Chapter 18</b>	<b>Endodontic Periodontal Inter-relationship</b>	<b>288</b>
	• Introduction • Relationship of pulp and periodontium: developmental aspects • Pathways of communication • Pulpal pathology and the periodontium • Periodontitis and pulpal pathology • Definition and classification • Diagnosis • Treatment • Root resection • Hemisection • Conclusion • Key points • Bibliography	
<b>Chapter 19</b>	<b>Restorative Considerations in Root-Filled Teeth</b>	<b>298</b>
	• Introduction • Restoration of root-filled teeth: impact on clinical outcome • Structural considerations in restored root-filled teeth • Restoration of root-filled teeth: Preoperative assessments • Post systems • Post and core systems • Management of root-filled teeth: techniques and clinical aspects • Conclusion • Bibliography	
<b>Chapter 20</b>	<b>Management of Discoloured Teeth</b>	<b>330</b>
	• Introduction • Classification of tooth discolouration • Mechanism of tooth discolouration • Dental bleaching • Sequelae to dental bleaching • Alternatives to bleaching • Bibliography	

<b>Chapter 21</b>	<b>Endodontic Emergencies</b>	<b>345</b>
	• Introduction • Classification • Before treatment • During treatment • Treatment regimens • Emergencies after treatment • Vertical root fracture • Bibliography	
<b>Chapter 22</b>	<b>Single-Visit Endodontics</b>	<b>353</b>
	• Introduction • Postoperative pain and failure • Advantages and disadvantages of single-visit endodontics • Indications and contraindications • Bibliography	
<b>Chapter 23</b>	<b>Lasers In Endodontics</b>	<b>358</b>
	• Introduction • Properties of laser light • Time modes of operation • Anatomic complexities of root canals • Laser-assisted root canal sterilization • Root canal shaping • Apex sealing • Indications for laser-assisted endodontics • Conclusion • Bibliography	
<b>Chapter 24</b>	<b>Microscopes in Endodontics</b>	<b>368</b>
	• Introduction • History • Misconceptions about surgical operating microscopes • Conclusion • Bibliography	
<b>Chapter 25</b>	<b>Problem Solving in Endodontic Access Openings, Cleaning, Shaping, and Root Canal Obturation</b>	<b>374</b>
	• Introduction • Problem-solving challenges in coronal access opening • Problem-solving concepts in determination of canal working length • Problem solving during cleaning and shaping of root canal system • Problem-solving challenges in filling (obturation) the root canal • Bibliography	
	<i>Glossary</i>	<b>415</b>
	<i>Index</i>	<b>425</b>



# Introduction and Scope of Endodontics

Anil Kohli and V Gopikrishna

## DEFINITION OF ENDODONTOLOGY AND ENDODONTICS

The consensus report of the European Society of Endodontology (1994) defines this discipline as:

*Endodontology is that branch of dental science concerned with the study of form, function, health of, injuries to and diseases of the dental pulp and periradicular tissues, and their treatment. The etiology and diagnosis of dental pain and disease are considered to be integral parts of endodontic practice. Endodontic treatment encompasses any procedure that is designed to maintain the health of all, or part of, the pulp. When the pulp is diseased or injured, treatment is aimed at maintaining or restoring the health of the periradicular tissues. When pulpal disease has spread to the periradicular tissues, treatment are aimed at restoring them to normal; this is usually achieved by root canal treatment or in combination with endodontic surgery.*

## BRIEF INTRODUCTION TO PULPAL / PERIAPICAL DISEASE

Pulp disease is characterized by inflammation, which is common with inflammatory responses in other parts of the body caused by any type of injury. The principal cause for this persistent and irreversible damaging inflammatory process is the bacterial infection of the pulp space. This process culminates in the ultimate necrosis of the pulpal tissue along with bacterial invasion and colonization. This progressively leads to periradicular inflammation, which is radiographically visualized as a radiolucency, with or without clinical symptoms.

In summary, a breach in the integrity of the tooth (first line of defence), exposes the dentine

and allows the pulp to be stimulated. Death of the pulp tissue removes the second line of defence and leads to the final- and third-defensive barrier, the periradicular inflammatory lesion.

The dental pulp may also be killed by acute traumatic injury to the tooth and dentoalveolar process, where infection may be delayed for many years unless there is a breach in the tooth structure allowing bacteria to invade. A rationale approach to the management of these inflammatory diseases requires an understanding of the normal structure and function of teeth and their supporting structures and the pathogenesis of the diseases.

In principle, the treatment approaches consist of eradication of the bacterial infection using biomechanical debridement with the help of instruments, in conjunction with chemical antibacterial agents in the form of irrigants and medicaments, to help disinfect and sterilize the pulp space and surrounding dentine and prevent its recontamination by using various obturation or filling materials that create an environment within which the body is able to effect healing. Treatment of pulpal inflammation by preserving the pulp tissue is called *pulp therapy* and treatment of periapical inflammation by eradicating infected pulp tissue to allow periradicular tissues to heal is called *root canal treatment*.

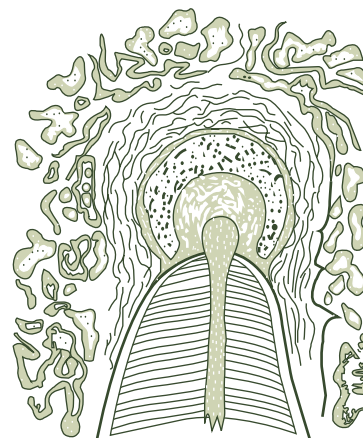## Scope of Endodontics

The extent of the subject has been radically altered in the past few decades. Formerly, endodontic treatment confined itself to root canal filling techniques by conventional methods; even endodontic surgery, which is an extension of these methods, was

# Chapter 3

## Rationale of Endodontic Treatment

*V Gopikrishna and Anil Kohli*



### PULPAL AND PERIRADICULAR REACTIONS TO STIMULI

Damage to the calcified structure of teeth and to the supporting tissues by harmful stimuli may culminate into changes in the pulp and the periradicular tissues. Noxious stimuli can be either physical, chemical, or bacterial and can produce either reversible or irreversible changes in the pulp and periradicular tissues depending on the following:

1. Duration of the stimulus
2. Intensity of the stimulus
3. Pathogenicity of the stimulus
4. The host's ability to resist the stimulus
5. the host's ability to repair tissue damage

Based upon these grounds, it can be comprehended that mild-to-moderate noxious stimuli to the pulp may produce the following results:

1. Sclerosis of the dentinal tubules
2. Formation of tertiary dentine
3. Cause reversible inflammation

Irreversible inflammatory changes caused by severe injury can lead to necrosis of the pulp and ensuing pathologic alterations in the periradicular tissues. The inflammatory response of the connective tissue of the dental pulp is modified because of its surroundings. As the pulp is enclosed in the hard tissues with restricted portals of entry, it is an organ of terminal and restricted circulation with no well-organized collateral circulation. Moreover, there exists limited space to expand during the inflammatory reaction.

Hence, it is mandatory for us to understand the fundamentals of inflammation and the various cells involved in this process for us to be able to understand pulpo-periapical pathophysiology better.

### INFLAMMATION

#### Definition and Causes

Inflammation is defined as the local response of living mammalian tissues to injury due to any agent. It is a body defence reaction in order to eliminate or limit the spread of injurious agent as well as to remove the consequent necrosed cells and tissues.

The agents causing inflammation may be given as:

1. Physical agents such as heat, cold, radiation, and mechanical trauma
2. Chemical agents such as organic and inorganic poisons
3. Infective agents such as bacteria, viruses, and their toxins
4. Immunological agents such as cell-mediated and antigen-antibody reactions

Thus, inflammation is distinct from infection—the former being a protective response by the body while the latter is invasion into the body by harmful microbes and their resultant ill-effects by toxins. Inflammation involves two basic processes with some overlapping, namely, early inflammatory response and later followed by healing. Though both these processes generally have protective role against injurious agents, inflammation and healing may cause considerable harm to the body as well, for example, anaphylaxis to bites by insects or reptiles, drugs, toxins, atherosclerosis, and chronic rheumatoid arthritis.

#### Signs of Inflammation

The Roman writer Celsus in 1st century AD, named the famous four cardinal signs of inflammation as:

- Rubor (redness)
- Tumour (swelling)

**Table 3.2** Cellular mediators of inflammation

Morphology	Features	Mediators
Polymorphonuclear neutrophils	<ul style="list-style-type: none"> <li>Initial phagocytosis of bacteria and foreign body</li> <li>Acute inflammatory cell</li> </ul>	<ul style="list-style-type: none"> <li>Primary granules</li> <li>Secondary granules</li> <li>Tertiary granules</li> <li>Reactive oxygen metabolites</li> </ul>
Monocyte/macrophages	<ul style="list-style-type: none"> <li>Bacterial phagocytosis</li> <li>Chronic inflammatory cell</li> <li>Regulates lymphocytes response</li> </ul>	<ul style="list-style-type: none"> <li>Acid and neutral hydrolases</li> <li>Cationic protein</li> <li>Phospholipase</li> <li>Prostaglandin, leukotrienes</li> <li>IL-1</li> </ul>
Lymphocyte	<ul style="list-style-type: none"> <li>Humoral and cell mediated immune response</li> <li>Chronic inflammatory cell</li> <li>Regulates macrophage response</li> </ul>	<ul style="list-style-type: none"> <li>B-cells: antibody production</li> <li>T-cells: delayed hypersensitivity, cytotoxicity</li> </ul>
Plasma cell	<ul style="list-style-type: none"> <li>Derived from B-cells</li> <li>Chronic inflammatory cells</li> </ul>	<ul style="list-style-type: none"> <li>Antibody synthesis</li> <li>Antibody secretion</li> </ul>
Eosinophil	<ul style="list-style-type: none"> <li>Allergic states</li> <li>Parasitic infestations</li> <li>Chronic inflammatory cells</li> </ul>	<ul style="list-style-type: none"> <li>Reactive oxygen metabolites</li> <li>Lysosomal</li> <li>PGE<sub>2</sub> synthesis</li> </ul>
Basophil/mast cell	<ul style="list-style-type: none"> <li>Receptor for IgE molecules</li> <li>Electron dense granules</li> </ul>	<ul style="list-style-type: none"> <li>Histamine</li> <li>Leukotrienes</li> <li>Platelet activating factor</li> </ul>

However, granules of eosinophils are richer in myeloperoxidase than neutrophils and lack lysozyme. High level of steroid hormones leads to fall in the number of eosinophils and even their disappearance from blood.

The absolute number of eosinophils is increased in the following conditions and, thus, they partake in inflammatory responses associated with these conditions:

- Allergic conditions
- Parasitic infestations
- Skin diseases
- Certain malignant lymphomas

### **BASOPHILS (MAST CELLS)**

The basophils comprise about 1% of circulating leucocytes and are morphologically and pharmacologically similar to mast cells of tissue. These cells contain coarse basophilic granules in the cytoplasm and a polymorphonuclear nucleus. These granules are laden with heparin and histamine. Basophils and mast cells have receptors for IgE and degranulate when cross linked with antigen.

The roles of these cells in inflammation are the following:

- in immediate and delayed type of hypersensitivity reactions and
- release of histamine by IgE-sensitized basophils

### **LYMPHOCYTES**

Next to neutrophils, these cells are most numerous of the circulating leucocytes (20%–45%). Apart from blood, lymphocytes are present in large numbers in spleen, thymus, lymph nodes, and mucosa-associated lymphoid tissue (MALT). They have scanty cytoplasm and consist almost entirely of nucleus.

Besides their role in antibody formation (B-lymphocytes) and in cell-mediated immunity (T-lymphocytes), these cells participate in the following types of inflammatory responses:

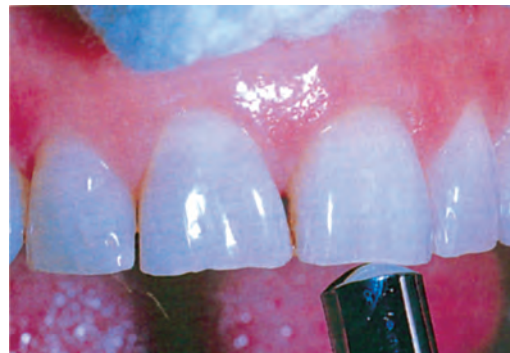- In tissues, they are dominant cells in chronic inflammation and late stage of acute inflammation
- In blood, their number is increased (lymphocytosis) in chronic infections such as tuberculosis



# Chapter 4

## Diagnosis

*V Gopikrishna*



### INTRODUCTION

The first step to successful endodontics is the identification of the patient's problem and the reason for his/her condition. Diagnosis is defined as 'the art and science of identifying a disease from its history, signs, symptoms, and results of investigations and tests, etc'. In other words, diagnosis is basically an art and a science because it is the interpretation of the data gathered by questioning and examining the patient, and the data given by scientific devices. Diagnosis in dentistry may be defined as 'the process whereby the data obtained from questioning, examining, and testing are combined by the dentist to identify the deviations from the normal. Ultimately, this will directly relate to what treatment, if any, will be necessary. No appropriate treatment recommendation can be made until all of the whys are answered. Therefore, a planned, methodical, and systematic approach to this investigatory process is crucial.

### Chief Complaint

This has to be recorded in the patient's own words in chronological order. This directs the clinician to streamline the steps towards clinical diagnosis. This is more important than the diagnostic tests performed.

**History and record:** The key to arrive at the right diagnosis lies in first listening to the patient. The patient's history in his/her own words would provide invaluable insight into the disease process. However, history taking should follow a systematic approach in the form and nature of the questions being asked to the patient. These include the following:

- Patient's chief complaint
- Past dental history

- Past medical history
- Any other relevant information

### Symptoms

Symptoms are the basic units of information that help to make a final diagnosis of the problem. Systematic recording of the patient's symptoms and a careful analysis of them with the results of tests and investigations lead to the correct diagnosis.

Symptoms can be classified into two types:

1. Subjective symptoms: These are given to the clinician by the patient and are those experienced by the patient himself
2. Objective symptoms: These are found out by the clinician through various observations, tests, and investigations

### SUBJECTIVE SYMPTOMS

The patient's chief complaint is the best starting point for arriving at a correct diagnosis. A completed medical form concerning the patient's past medical and dental history consists of subjective symptoms. A chief complaint normally relates to pain, swelling, and lack of function or aesthetics. The fundamental principle in diagnosis is to begin by asking the patient for his/her chief complaint.

**Pain:** The most common condition for seeking the dental treatment is pain. Questioning about the pain can aid the diagnostician in developing a tentative diagnosis quickly.

One should ask the patient about the following details:

1. The kind of pain
2. Its location
3. Its duration

has been used to show that when teeth have been cooled, non-vital teeth were slower to re-warm than vital teeth.

### Disadvantage

Teeth must be isolated with rubber dam, after which a period of acclimatization is necessary prior to imaging. The technique is complex and also requires the subjects to be rested for 1 h prior to testing.

## TRANSMITTED-LIGHT PHOTOPLETHYSMOGRAPHY

Transmitted—light photoplethysmography (TLP) is one of the non-invasive techniques to monitor pulpal blood flow, in addition to LDF, and has been applied to the pulp in cats, dogs, and adult humans. It has been suggested that TLP has the advantage of less signal contamination derived from periodontal blood flow than that recorded by LDF. Photoplethysmography has been compared with LDF in experiments on skin, and found to be of similar value. Miwa et al, proved that TLP can detect pulpal blood flow in young permanent teeth.

## LASER DOPPLER FLOWMETRY

Laser Doppler flowmetry (LDF) is a non-invasive method to assess blood flow in microvascular systems, for example, in retina, gut mesentery, renal cortex, and skin. Its use in teeth was first described by Gazelius. Since then, the technique has found application in monitoring dynamic changes in pulpal blood flow in response to pressure changes and following administration of local anaesthesia.

### Principle

This technique utilizes a beam of infrared light produced by a laser that is directed into the tissue. As light enters the tissue, it is scattered and adsorbed by moving red blood cells and stationary tissue elements. Photons that interact with moving red blood cells are scattered and frequently shifted according to the Doppler principle. Photons that interact with stationary elements are scattered but not Doppler shifted. A portion of the light is returned to the photo detector, and a signal is produced. Since red blood cells

represent the vast majority of moving objects within the tooth, measurement of Doppler-shifted backscattered light is interpreted as an index of pulpal or pulpal blood flow.

LDF can differentiate healthy from non-vital teeth used to determine pulpal vitality in traumatized teeth at a stage when conventional clinical findings are inconclusive and LDF readings are extremely accurate in differentiating a re-vascularized (vital) tooth from a necrotic pulp tooth.

### Disadvantages

1. Motion artefact due to uncontrolled movement of the probe when placed on teeth.
2. Need of modified mouth guards or splints to stabilize the measuring probe on tooth to obtain accurate and reproducible readings.
3. Blood pigments within a discoloured tooth crown can interfere with laser light transmission.
4. Periodontium and other neighbouring gingival tissues contribute to the pulpal blood flow signalling gingival false-positive results.

## PULSE OXIMETER

It is a non-invasive oxygen saturation monitoring device widely used in medical practice for recording blood oxygen saturation levels during the administration of intravenous anaesthesia through the use of finger, foot, or ear probes. It was invented by Takuo Aoyagi, a biomedical engineer working for the Shimadzu Corporation in Kyoto, Japan, in the early 1970s. Pulse oximetry is a completely objective test, requiring no subjective response from the patient that directly measures blood oxygen saturation levels.

### Principle

The *pulse oximeter sensor* (POS) consists of two light-emitting diodes, one to transmit red light (640 nm) and the other to transmit infrared light (940 nm) and a photo-detector on the opposite side of the vascular bed. The light-emitting diode transmits red infrared light through a vascular bed such as the finger or ear. Oxygenated haemoglobin and deoxygenated haemoglobin absorb different amounts of red infrared light. The pulsatile change in the blood volume causes periodic changes in the amount of red infrared light absorbed by the vascular bed before

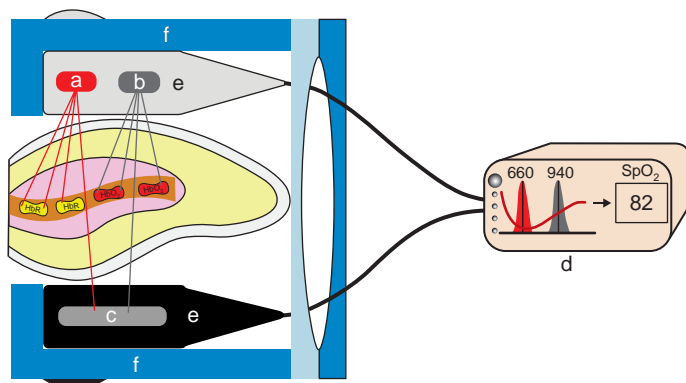
reaching the photodetector. The relationship between the pulsatile change in the absorption of red light and the pulsatile change in the absorption of infrared light is analyzed by the pulse oximeter to determine the saturation of arterial blood (Fig. 4.11).

The pulse oximeter equipment consists of a *pulse oximeter monitor* (POM) that gives the digital display of oxygen saturation values. This POM is connected to a POS that is designed to anatomically conform to the area where oxygen saturation values have to be assessed. For example, ear POS, finger sensor, and toe sensor. The POS is held in place with a *sensor holder* to ensure accurate adaptation of the sensor in the area being assessed.

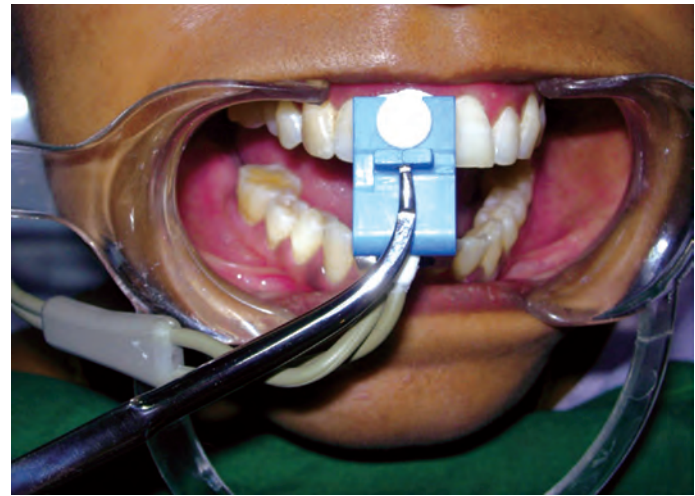
Gopikrishna et al (2006), developed a custom-made POS holder for an existing Nellcor multi-site sensor and showed the utility of the pulse oximeter dental probe in the assessment of human pulp vitality. Gopikrishna et al, compared the accuracy of the pulse oximeter dental probe with thermal and electrical pulp test, it was found that the probability of a negative-test result representing a vital pulp was 81% with the cold test, 74% with the electrical test, and 100% for pulse oximeter. The probability of a positive-test result representing a necrotic pulp was 92% with the cold test, 91% with the electrical test, and 95% for pulse oximeter.

### Efficacy of Pulse Oximetry in Recently Traumatized Teeth

Gopikrishna et al, compared the efficacy of a custom-made pulse oximeter dental probe with the electric pulp testing and thermal testing for measuring pulp



**Figure 4.11** Mechanism of dental pulse oximeter: (a) Light emitting diode emitting red light at 660 nm, (b) Light emitting diode emitting infrared light at 940 nm, (c) Photodetector, (d) Pulse oximeter monitor, (e) Pulse oximeter sensor, and (f) Custom-made pulse oximeter sensor holder. HbO<sub>2</sub>, oxygenated haemoglobin; HbR, deoxygenated haemoglobin; SpO<sub>2</sub>, oxygen saturation of arterial blood.




**Figure 4.12** Pulse oximeter dental probe placed on patient's tooth.

vitality status of recently traumatized permanent teeth. The proportion of recently traumatized teeth showing a positive responsiveness in thermal/electric pulp tests increased from no teeth showing responsiveness on day 0 to 29.40% teeth on the 28th day, 82.35% of teeth at 2 months, and 94.11% teeth at 3 months. However, pulse oximeter gave positive-vitality readings that remained constant over the study period from day 0 to 6 months in all patients (Fig. 4.12).

### BIBLIOGRAPHY

1. Andreasen FM and Andreasen JO. 'Crown fractures', in FM Andreasen and JO Andreasen (eds), *Textbook and Color Atlas of Traumatic Injuries to the Teeth* (3rd ed), p. 245. Copenhagen: Munksgaard, 1994.
2. Andreasen FM and Andreasen JO. 'Luxation injuries', in FM Andreasen and JO Andreasen (eds), *Textbook and Color Atlas of Traumatic Injuries to the Teeth* (3rd ed), pp. 353–54. Copenhagen: Munksgaard, 1994.
3. Barker BCW and Ehrmann EH. 'Human pulp reactions to a ducocorticosteroid antibiotic compound'. *Aust Dent J* 14: 104–19, 1969.
4. Bender IB, Landau MA, Fonseca S, and Trowbridge HO. 'The optimum placement-site of the electrode in electric pulp testing of the 12 anterior teeth'. *J Am Dent Assoc* 118: 305–10, 1989.
5. Bender IB and Seltzer S. 'The effect of periodontal disease on the pulp'. *Oral Surg Oral Med Oral Pathol* 33: 458–74, 1972.
6. Bernick S and Nedelman C. 'Effect of ageing on the human pulp'. *J Endod* 1: 88–94, 1975.



# Microbiology in Endodontics

*Suma Ballal and V Gopikrishna*

## INTRODUCTION

Invention of the microscope by Antony van Leeuwenhoek in the 17th century has opened up new vistas in the diagnosis and management of diseases. On the basis of cultivation, and microscopic and molecular studies it is now known that microorganisms are the major cause of most of the diseases involving the pulp and periapex. Almost all these microbes originate from the oral cavity, and rarely from other parts of the body or the general environment. The unique milieu of the root canal system favours their growth and survival.

A proper understanding of the microorganisms associated with endodontic diseases is necessary to arrive at a proper diagnosis and formulate a suitable treatment plan. On the basis of this knowledge, current endodontic procedures would aim at complete debridement of the root canal and disruption of the microbial ecosystem causing the disease. Ideally, such treatment procedures should sterilize the root canal, that is, eliminate all the microorganisms present in the entire root canal. However, considering the complex canal anatomy, available instruments, and techniques, fulfilling this goal is almost certainly impossible. At present, the only reachable goal seems to be to identify and reduce bacterial population to subcritical levels that are compatible to healing.

Entrenched in the privileged anatomic localization of the root canal, bacteria are beyond the reach of the host defences and systemically administered antibiotics. Hence, management of endodontic infections can be successfully achieved by means of professional intervention. The two major steps involved in reaching this goal are chemo-mechanical preparation and a three-dimensional obturation. A thorough chemo-mechanical preparation is extremely important, as the endodontic instrumentation and irrigation primarily act on the main canal,

which is the most voluminous area of the system and harbours the largest number of bacterial cells. Entombment of bacteria, especially those remaining on the root canal wall or within the dentinal tubules, is said to be one of the aims of obturation.

Earlier on, intracanal medicaments were being used extensively during root canal treatment. Currently, the only indication for the use of intracanal medicaments during interappointment periods is to supplement the antibacterial effect of chemo-mechanical procedures especially in the weeping canals and to aid in eliminating persistent bacteria.

This chapter aims at highlighting the role of microorganisms in endodontic diseases and their effective management.

**Clinical significance:** A thorough chemo-mechanical preparation along with three-dimensional obturation is the primary means of eliminating microorganisms present within the root canal system. Intracanal medicaments have a very limited role to play (primarily in the weeping canal).

## HISTORY OF ASSOCIATION BETWEEN MICROBES AND ENDODONTIC DISEASE

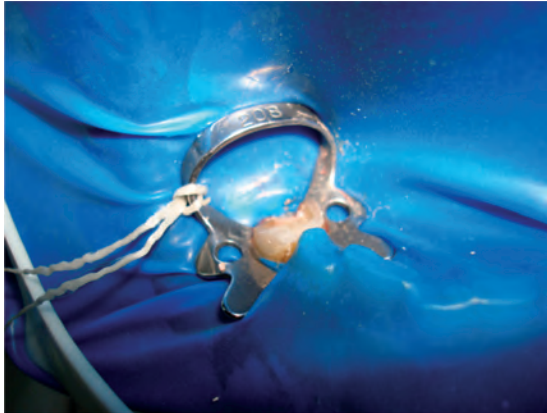
- **17th century:** Antony van Leeuwenhoek first described oral microbiota using the single lens microscope. He termed these microorganisms as 'animalcules'
- **1890:** WD Miller considered to be the father of oral microbiology authored a book, *Microorganisms of the Human Mouth*. He became the first researcher to associate the presence of bacteria and pulpal disease
- **1965:** A classic study by Kakehashi et al (1965), confirmatively proved that bacteria caused pulpal and periradicular diseases. They observed that



**Table 5.1** Bacteria isolated from the root canals showing primary infection with apical periodontitis (Courtesy: Stock C, Walker R, and Gulabivala K. Endodontics (3rd ed). Elsevier, 2004.)

Aerobes	Facultative Anaerobes	Anaerobes
<b>Gram-positive cocci</b> <i>Dietzia maris</i> <i>Micrococcus luteus</i> <i>M. lylae</i>	<b>Gram-positive cocci</b> <i>Enterococcus faecalis</i> <i>E. faecium</i> <i>E. hirae</i> <i>Gemella haemolysans</i> <i>G. morbillorum</i> <i>Leuconostoc</i> sp. <i>Pediococcus acidilactici</i> <i>Rothia</i> sp. <i>Staphylococcus aureus</i> <i>S. epidermidis</i> <i>S. hominis</i> <i>S. warneri</i> <i>Stomatococcus mucilaginosus</i> <i>Streptococcus anginosus</i> <i>Str. constellatus</i> <i>Str. gordonii</i> <i>Str. infantis</i> <i>Str. intermedius</i> <i>Str. mitior</i> <i>Str. mitis</i> <i>Str. mutans</i> <i>Str. oralis</i> <i>Str. pyogenes</i> <i>Str. salivarius</i> <i>Str. sanguinis</i> <i>Str. sobrinus</i> <i>Str. suis</i>	<b>Gram-positive cocci</b> <i>Peptococcus</i> sp. <i>Peptostreptococcus anaerobius</i> <i>P. asaccharolyticus</i> <i>P. magnus</i> <i>P. micros</i> <i>P. prevotii</i> <i>Ruminococcus</i> sp.
<b>Gram-positive rods</b> <i>Arthrobacter</i> sp. <i>Brachybacterium</i> sp.		<b>Gram-positive rods</b> <i>Bifidobacterium</i> <i>Eubacterium brachy</i> <i>E. lentum</i> <i>E. nodatum</i> <i>Eubacterium</i> sp. <i>E. timidum</i> <i>Slackia exigua</i>
<b>Gram-negative cocci</b> <i>Neisseria</i> sp.		<b>Gram-negative cocci</b> <i>Acidaminococcus</i> sp. <i>Veillonella dispar</i> <i>V. parvula</i>
<b>Gram-negative rods</b> <i>Acinetobacter wolffii</i> <i>Campylobacter sputorum</i> <i>Kingella</i> sp. <i>Pseudomonas aeruginosa</i> <i>Wolinella curva</i> <i>W. recta</i>	<b>Gram-positive rods</b> <i>Actinomyces meyeri</i> <i>A. naeslundii</i> <i>A. odontolyticus</i> <i>A. radidentis</i> <i>A. viscosus</i> <i>Bacillus flexus</i> <i>B. megaterium</i> <i>B. pumilus</i> <i>Corynebacterium diphtheriae</i> <i>Lactobacillus fermentum</i> <i>L. gasseri</i> <i>L. casei</i> <i>L. rhamnosus</i> <i>Propionibacterium acnes</i> <i>P. propionicum</i>	<b>Gram-negative rods</b> <i>Acidaminobacter</i> sp. <i>Bacteroides</i> sp. <i>Clostridium</i> sp. <i>Fibrobacter</i> sp. <i>Fusobacterium necrophorum</i> <i>F. nucleatum</i> <i>F. varium</i> <i>Leptotrichia</i> sp. <i>Megamonas</i> sp. <i>Mitsuokiella</i> sp. <i>Porphyromonas asaccharolyticus</i> <i>P. endodontalis</i> <i>P. gingivalis</i> <i>Prevotella buccae</i>





## Isolation and Infection Control in Endodontics

*Sanjay Miglani and V Gopikrishna*

### ISOLATION IN ENDODONTICS

#### Introduction

Isolation is one of the most important parts of successful endodontic treatment. Rubber dam is the most recommended way of isolation in endodontics. It was introduced by SC Barnum, a New York City dentist, in 1864. It defines the operating field by isolating one or more teeth from oral environment. To maintain a safe and aseptic operating technique, rubber dam application is mandatory. It is the most efficient and reliable safeguard against bacterial contamination from saliva and accidental swallowing of root canal instruments, which can result in medico-legal problems to the dentist. All endodontic procedures should be performed under rubber dam isolation.

#### ADVANTAGES OF USING RUBBER DAM

1. **To achieve dry and clean operating field:** Operative procedures such as caries removal, tooth preparation, and restoration can be best performed in a dry field without any contamination
2. **To improve access and visibility:** It provides maximum access and visibility by controlling moisture and retracting soft tissues
3. **To improve properties of dental materials:** By preventing moisture contamination it promotes improved properties of dental materials
4. **To protect the patient and the operator**
  - Prevents aspiration, swallowing of endodontic instruments, or debris produced during operative procedures

- Prevents damage to oral soft tissues from various solutions and medicaments used during operative procedures
  - Prevents mercury exposure during amalgam removal
5. **To improve operator efficiency**
    - Excessive patient conversation is avoided
    - Quadrant restorative procedures are facilitated
    - Improved quality of restorative services

#### ORAL CONDITIONS THAT PRECLUDE USE OF RUBBER DAM

1. Partially erupted teeth and some third molars unable to support a retainer
2. Excessively malpositioned teeth
3. Asthmatic patients
4. Latex allergy or some psychological reasons; however, latex free rubber dams are also available

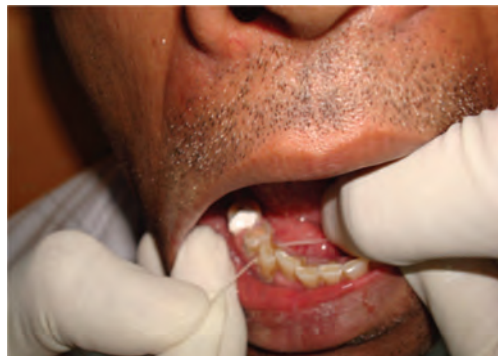#### Armamentarium

##### Rubber dam material

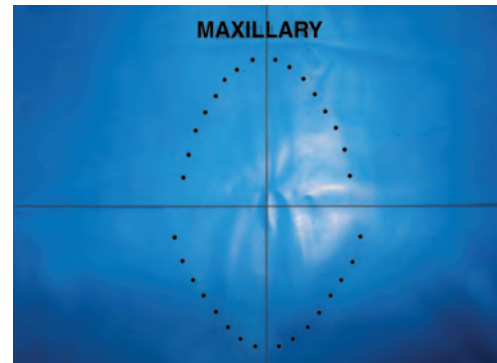
Commercially available in various sizes (Fig. 6.1).



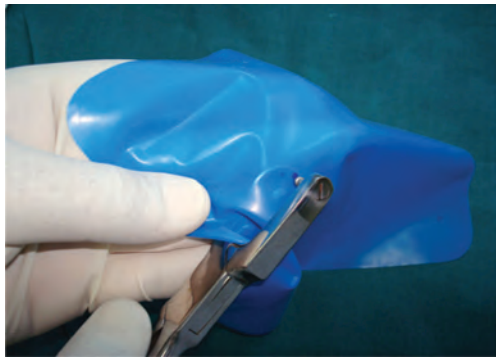
**Figure 6.1** Rubber dam sheets.



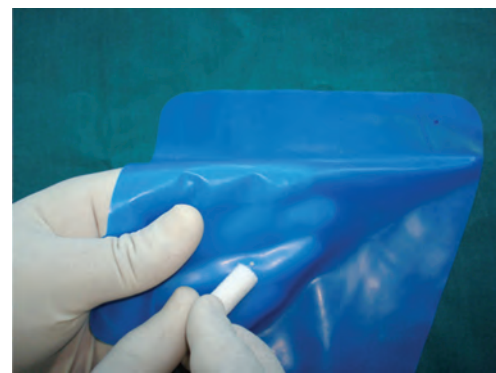
(a)



(b)



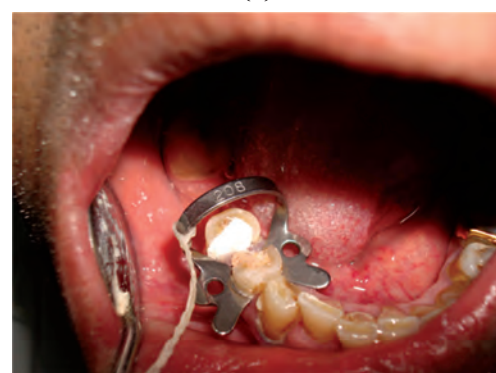(c)



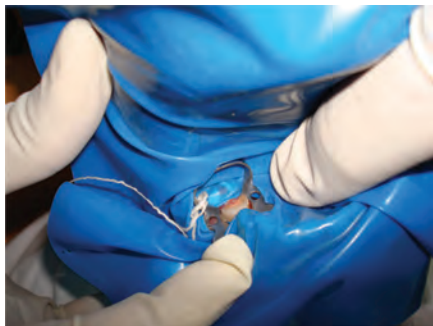
(d)



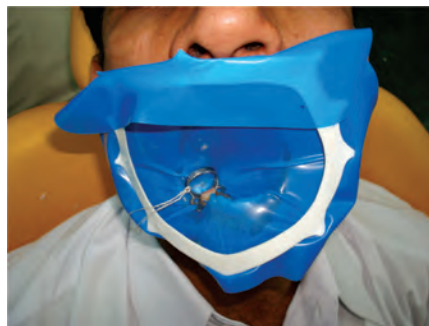(e)



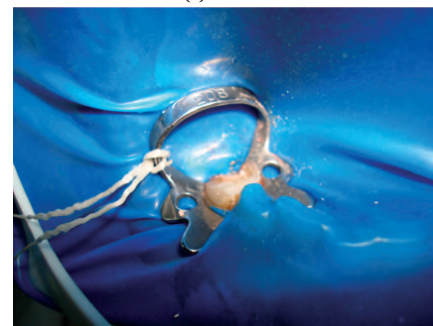
(f)



(g)

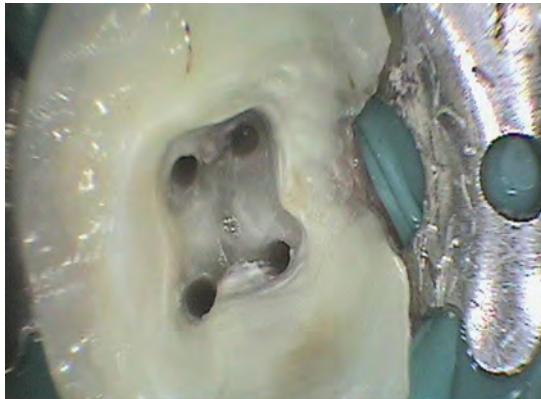

(h)



(i)

**Figure 6.11** Steps of rubber dam application (a) Identify the proximal contact and apply lubricant, (b) Marking the hole on sheet with help of template, (c) Punching of holes on sheet, (d) Lubricating the dam, (e) Selection of retainer, (f) Placement of retainer over the tooth with dental floss, (g) Position the dam over retainer with forefingers, (h) Attaching the frame, and (i) Dam secured in place.



## Root Canal Morphology and Access Preparation

*V Gopikrishna*

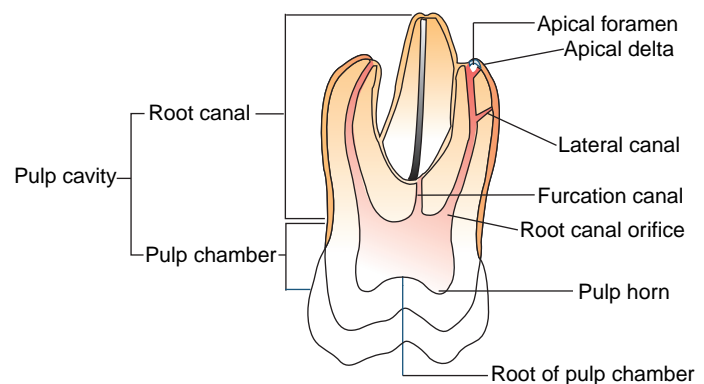
### INTRODUCTION

Access is an essential element to successful endodontics. Preparing the endodontic access cavity is a critical step in a series of procedures that potentially leads to the three-dimensional obturation of the root canal system. Access cavities should be cut so that the pulpal roof, including all overlying dentine, is removed. The size of the access cavity is dictated by the position of the orifice(s). The axial walls are extended laterally such that the orifice(s) is just within this outline form. The internal walls are flared and smoothed to provide straight-line access into the orifice and the root canal system. Additionally, access preparations are expanded to eliminate any coronal interference during subsequent instrumentation. Access objectives are confirmed when all the orifices can be visualized without moving the mouth mirror. Ideally, endodontic access cavities should parallel the principle of restorative dentistry where the axial walls of a 'finished' preparation taper provide draw for a wax pattern. Cleaning and shaping potentials are dramatically improved when instruments conveniently pass through the occlusal opening, effortlessly slide down smooth axial walls and are easily inserted into the orifice. Spacious access cavities are an opening for canal preparation.

### COMPONENTS OF ROOT CANAL SYSTEM

The entire space in the dentine of the tooth where the pulp is housed is called the pulp cavity (Fig. 9.1). Its outline corresponds to the external contour of the tooth. However, factors such as physiologic ageing, pathology, and occlusion shape its size by the production of secondary and tertiary dentine and cementum.

The pulp cavity is divided into two portions: the pulp chamber, which is located in the anatomic crown of the tooth and the pulp or root canal(s), which are found in the anatomic root. Other features include pulp horns, lateral, accessory and furcation canals, canal orifices, intercanal connections, apical deltas, and apical foramina. A root canal begins as a funnel-shaped canal orifice generally present at or slightly apical to the cervical line and ends at the apical foramen which opens onto the root surface between 0 and 3 mm from the centre of the root apex. Nearly all root canals are curved, particularly, in a facial-lingual direction. These curvatures may pose problems during shaping and cleaning procedures because they are not evident on a standard facial radiograph. Angled views are necessary to determine their presence, direction, and severity. A curvature may be a gradual curve of the entire canal or a sharp curvature near the apex. Double 'S-shaped' canal curvatures can also occur. In most cases, the number of root canals corresponds with the number of roots, but an oval-shaped root



**Figure 9.1** Components of the root canal.

**Table 9.2** Morphology of the mandibular permanent teeth\*

Tooth	Root	No. of Teeth	Canals with Lateral Canals	Position of Lateral Canals				Transverse Anastomosis between Canals	Position of Transverse Anastomosis				Position of Apical Foramen	
				Cervical	Middle	Apical	Furcation		Cervical	Middle	Apical	Central	Lateral	Apical Deltas
Central	—	100	20	3	12	85	—	—	—	—	—	25	75	5
Lateral	—	100	18	2	15	83	—	—	—	—	—	20	80	6
Canine	—	100	30	4	16	80	—	—	—	—	—	30	70	8
First premolar	—	400	44.3	4.3	16.1	78.9	0.7	32.1	20.6	52.9	26.5	15	85	5.7
Second premolar	—	400	48.3	3.2	16.4	80.1	0.3	30	0	66.7	33.3	16.1	83.9	3.4
First molar	Mesial	100	45	10.4	12.2	54.4	↑	63	12	75	13	22	78	10
							23							
	Distal	100	30	8.7	10.4	57.9	↓	55	10	72	18	20	80	14
Second molar	Mesial	100	49	10.1	13.1	65.8	↑	31	10	77	13	19	81	6
	Distal	100	34	9.1	11.6	68.3	↓	16	11	74	15	21	79	7

Note: Figures represent percentage of the total.

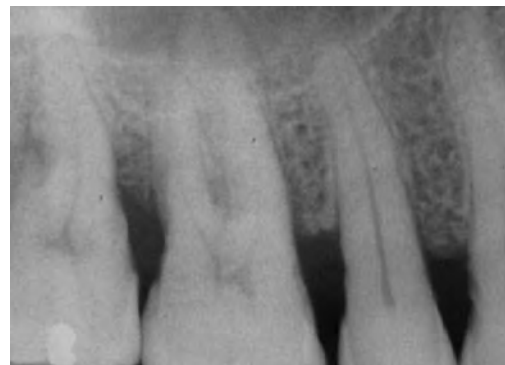\*Results published previously in: Vertucci FJ. 'Root canal anatomy of the human permanent teeth'. Oral Surg Oral Med Oral Pathol Oral Radiol Endod 58: 589–99, 1984.



# Chapter 10

## Dental Radiology

*V Gopikrishna and Anil Kohli*



### INTRODUCTION

Radiation is a form of energy distributed through space as a result of the solar energy. One ray in the spectrum differs from another mainly by its wavelength that is measured in terms of the angstroms. The smaller the wavelength of a 'ray' the greater its power of penetration through the substances. The range of X-rays is from  $10^{-7}$  to  $10^{-9}$  cm. X-rays are electromagnetic radiations. These were discovered by WC Roentgen in 1895.

### History of Dental Radiology

While doing some experiments Roentgen found that whenever a discharge tube is operated, a fluorescent screen placed nearby starts glowing, even if the tube is wrapped with black paper. He concluded that some electromagnetic waves are being produced by discharge tube in operation. Since the actual source for these radiations and other properties were not known at that time he called these glowing radiations 'X' rays.

### Mechanism of Production of X-rays

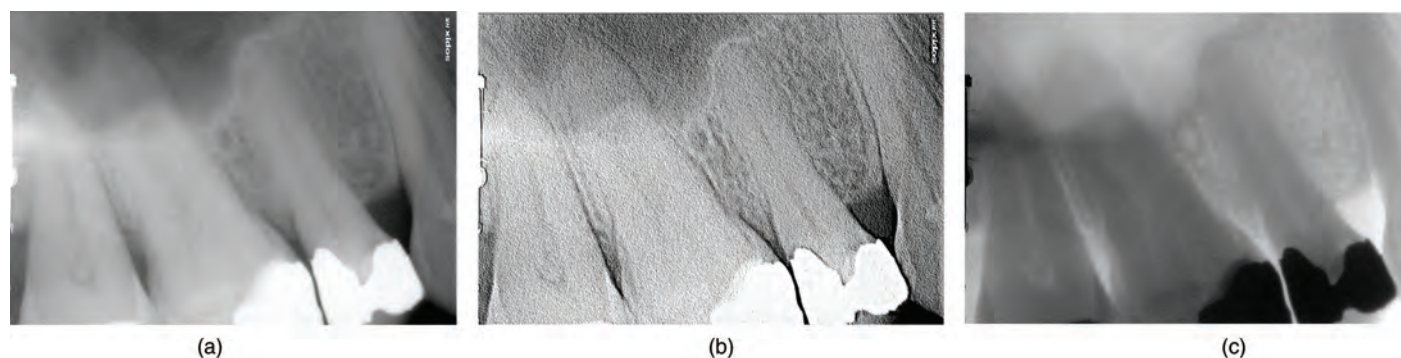
In modern X-ray tubes, we have a cathode and an anode hermetically sealed in an enveloping tube. By heating the cathode that consists of a tungsten filament, electrons are released. These electrons travel along the vacuum within the tube, towards the anode (again made of tungsten set in a molybdenum block) and strike the anode with tremendous force—thereby knocking off the electrons of the anode itself and taking the place of the latter in turn. It is this interchange of electrons that gives rise to a release of radiation energy from the anode; a type of ray (i.e. its wavelength) that depends on the speed and impact of the electrons at the anode that in turn is dependent upon the voltage applied. For diagnostic purposes in dentistry, 40,000 to 60,000 volts (40 to 60 kv) shall give rise to fairly good X-ray.

### Need for Prescribing Dental Radiograph


As a general principle, radiographs are indicated when there is a high probability of getting information about dental pathology that is not evident clinically.

1895	WC Roentgen	Discovery of X-rays
1896	O Walkhoff	First dental radiograph
1901	WH Rollins	Presented first paper on dangers of X-rays
1904	WA Price	Introduction of bisecting technique
1913	Eastman Kodak Company	Introduction of prewrapped dental films
1920	Eastman Kodak Company	Introduction of machine made film packets
1925	HR Raper	Introduction of bitewing technique
1947	FG Fitzgerald	Introduction of paralleling cone technique





**Figure 10.7** Radiovisuography (RVG): (a) Normal view, (b) Edge enhancement, and (c) Negative view.



**Figure 10.8** (a) Normal view, and (b, c) Colour enhanced views.

endodontic therapy in which multiple images frequently are needed

- **Loss of conventional films:** Most practices have relatively efficient ways to store conventional radiographs in their respective patient charts, but occasionally, a critical film comes loose from its holder, and it is lost without the possibility of retrieval. Assuming adequate back-up procedures are observed, there is no reason to lose stored digital radiographic images
- **Ease of use:** Some practitioners who are not comfortable with computers may debate this point. However, after a short learning period, accompanied with frequent use, the simple software necessary for use of digital radiography is easily mastered. The new wireless digital radiography concept has simplified the clinical procedure even more. This concept is easier, cleaner, and certainly faster than conventional radiography

#### Disadvantages

- **Wire attached to the sensor:** CCD-type sensors may be wired or wireless. With wired sensors, the presence of a wire attached to the sensor allows immediate

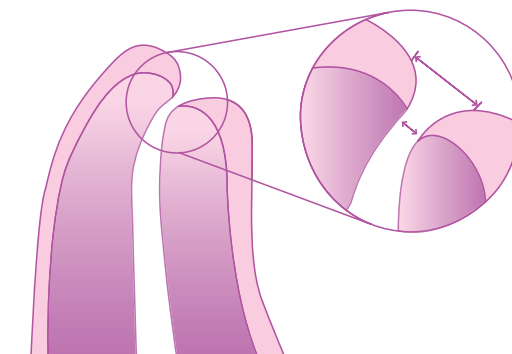
observation of the image. However, clinicians must work around the wire. This is not difficult, but mastering it requires some effort and a learning period. Phosphorus sensors do not provide immediate observation of the radiographic image, but they also do not have the objectionable wire. The elimination of the wire afforded by wireless sensors is a major advantage, but it must be considered in the light of the significant cost of a wireless sensor

- **Thickness of the sensor:** CCD sensors vary in thickness from more than 3 mm to more than 5 mm. Although this seems to be a major disadvantage, it is surprising to note the relative ease of use of CCD sensors in spite of their thickness. Wired sensors are not thinner than wireless sensors. Phosphorus sensors are thinner than CCD sensors, but they do not offer the advantage of immediate observation of the radiographic image
- **Rigidity of the sensor:** CCD sensors are rigid and can irritate the oral soft tissues and cause pain. If the patient experiences discomfort, the clinician can use soft foam attachments on the corners of the sensors to prevent pain. Phosphorus sensors are less rigid

# Chapter 11

## Working Length Determination

*V Gopikrishna and Abarajithan*



### INTRODUCTION

Complete cleaning of the root canal is the most critical step for a successful endodontic therapy that cannot be accomplished unless an accurate working length is determined. Numerous studies have proved the importance of confining instruments, irrigating solutions, and obturating materials in the canal space. Thus, it can be said that predictable endodontic success demands accurate determination of working length of the root canal and strict adherence to it, to create a small wound site and good healing conditions. Before we discuss the various methods for the determination of working length, we need to understand the anatomic considerations relating to it.

### DEFINITIONS

Working length is defined as the distance from a coronal reference point to the point at which canal preparation and obturation should terminate (American Association of Endodontists, 1998).

### Anatomical Considerations

**Anatomic apex** is defined as the tip or end of the root determined morphologically.

**Radiographic apex** is defined as the tip or end of the root determined radiographically.

**Apical foramen (major diameter)** is the main apical opening of the root canal. It is frequently eccentrically located away from the anatomic or radiographic apex.

**Apical constriction (minor diameter)** is the apical portion of the root canal having the narrowest diameter.

### Importance of Apical Constriction

It is the area (Fig. 11.1) that has the narrowest diameter in the entire root canal, thus, creating the smallest wound site and best healing conditions. Location of apical constriction ranges from 0.5 to 1.0 mm short of the anatomic apex.

### CEMENTO-DENTINAL JUNCTION

- It is the region where the dentine and cementum are united
- It is a histological landmark and cannot be located clinically or radiographically
- The cemento-dentinal junction (CDJ) does not always coincide with apical constriction
- It is located 0.5 to 3.0 mm short of anatomic apex

### SIGNIFICANCE OF WORKING LENGTH

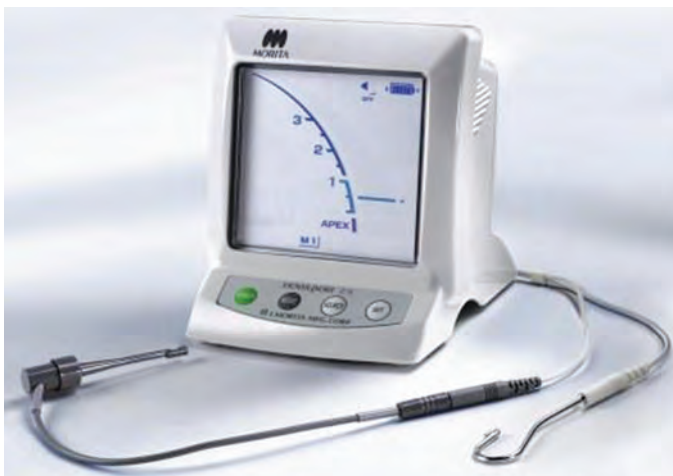- Working length determines the extent or limit to which instrumentation should be done
- Before determining a definite working length, there should be a straight line access for the canal orifice for unobstructed penetration of instrument into apical constriction
- Once apical stop is calculated, monitor the working length periodically because working length may change as curved canal is straightened
- Failure to accurately determine and maintain working length may result in length being more than normal, which will lead to postoperative pain, prolonged healing time, and lower success rate

can be different combinations of values of capacitance and resistance that provide the same impedance, and thus, the same foraminal reading. However, by using fourth-generation apex locators, this can be broken down into primary components and measures separately for better accuracy, and, thus, less chances of occurrence of errors (Figs 11.7 and 11.8.)

Although it is claimed to provide high accuracy, more studies are required for its confirmation.

### Basic Conditions for Accuracy of All EALs

Whatever is the generation of an apex locator there are some basic conditions, which ensure accuracy of their usage.



**Figure 11.7** Root ZX II Apex Locator. (Courtesy: J Morita.)



**Figure 11.8** Propex II Apex Locator. (Courtesy: Dentsply.)

1. Canal should be free from most of the tissues and debris
2. The apex locator works best in a relatively dry environment. However, extremely dry canals may result in low readings, that is, long working length
3. Cervical leakage must be eliminated and excess fluid must be removed from the chamber as this may cause inaccurate readings
4. If residual fluid is present in the canal, it should be of a low conductivity value, so that it does not interfere with the functioning of the apex locator. The descending order of conductivity of various irrigating solutions are the following: 5.25% NaOCl > 17% EDTA > Saline
5. Since EALs work on the basis of contact with canal walls and periapex, the better the adaptation of file to the canal walls, the more accurate is the reading
6. Canals should be free from any type of blockage, calcifications, etc.
7. Battery of the apex locator and other connections should be proper

### Uses of Apex Locators

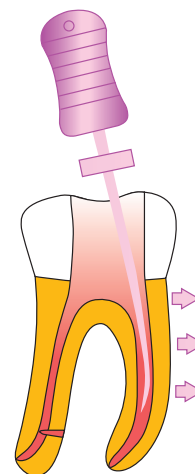
1. They provide objective information with a high degree of accuracy
2. They are useful in conditions where apical portion of canal system is obstructed by
  - a. Impacted teeth
  - b. Zygomatic arch
  - c. Tori
  - d. Excessive bone density
  - e. Overlapping roots
  - f. Shallow palatal vault
 In such cases, they can provide information, which radiographs cannot
3. They are useful in patients who cannot tolerate radiographic film placement because of gag reflex
4. In case of pregnant patients, they can be a valuable tool to reduce the radiation exposure
5. They can also be used in case of children who may not tolerate taking radiographs, disabled patients, and patients who are heavily sedated
6. They are valuable tool for
  - a. Detecting site of root perforations
  - b. Diagnosis of external and internal resorption that have penetrated root surface
  - c. Detection of horizontal and vertical root fracture
  - d. Determination of perforations caused during postpreparation
  - e. Testing pulp vitality
7. They are helpful in the root canal treatment of teeth with incomplete root formation, requiring apexification, and to determine working length in primary teeth



# Chapter 12

## Cleaning and Shaping of Root Canal System

*V Gopikrishna, M Kundabala, and Anil Kohli*



### INTRODUCTION

Successful endodontic therapy calls for optimized chemo-mechanical preparation and disinfection of root canal system, and three-dimensional obturation. Disinfection of root canal therapy mainly depends on the total elimination of microorganisms from the root canal system that will have a favourable outcome on the zone of infection around the periapical region. This can be achieved by creating an access to reach the intricacies of the root canal system, extirpating the pulpal debris, chemo-mechanically preparing the canal, placing an inter-appointment medicament and smear layer removal from the root canal wall, which can otherwise form a substrate for bacterial growth.

The technical evolution in the speciality of endodontics have been of great magnitude and profundity in the last 10 years, such as endodontic microscope, endosonics, accurate microchip computerized apex locators, flexible Ni-Ti files in rotary engines. These help the endodontist to treat the patients with greater precision, fewer procedural errors, less discomfort to the patient with more predictable efficient and reliable results. Currently, various changes have taken place in the technique of root canal preparation by making use of all these technical advances to get the best results. This chapter describes objectives, principles, and various techniques of preparation of the root canal system. Different techniques can be used in accordance to the clinical observations, research discoveries, and traditionally accepted values as well as

- Extent of enlargement
- Terminal point
- Type of root canal system

### Cleaning

Cleaning is removal of all the contents of root canal system such as organic substrates, microflora, bacterial by-products, food, caries, pulp stones, dense collagen, previous root canal filling material, and dentinal fillings. It allows easy access to files and irrigants during the shaping process.

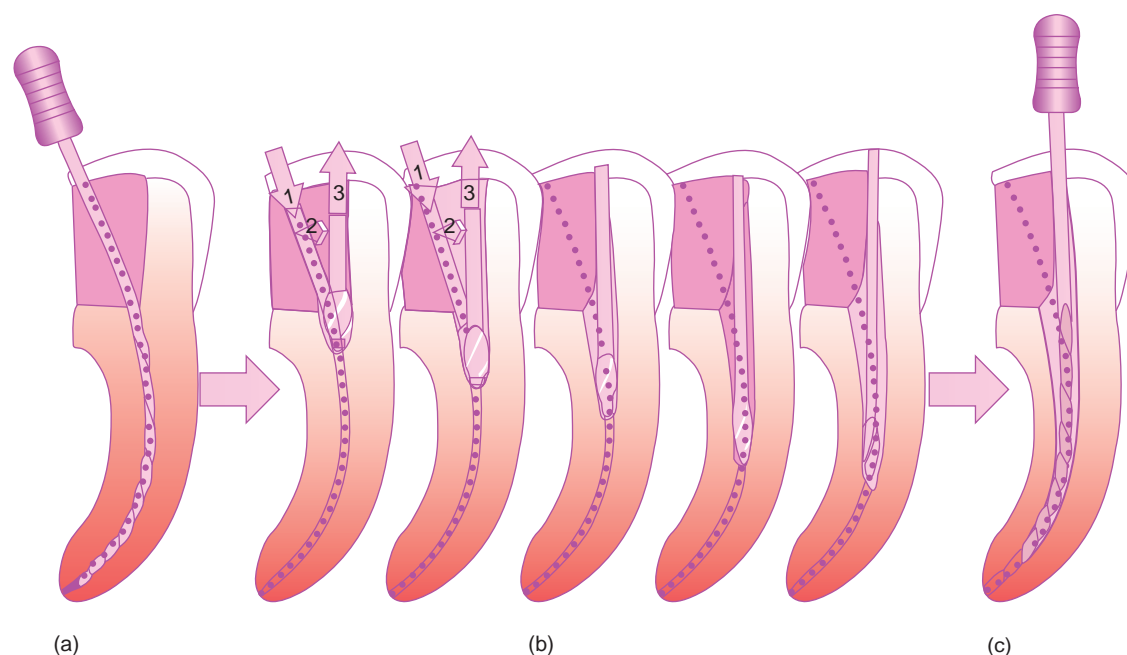
### Shaping

Shaping is done to remove all the contents from the root canal system, to work deep inside the canal, and to create a smooth, tapered opening to the terminus for three-dimensional obturation. It provides the specific cavity form which permits vertical pluggers to fit freely within the root canal system and to generate the hydraulics required to three-dimensionally obturate the gutta-percha and a microfilm of sealer into all foramina.

### Objectives of Shaping and Cleaning

The *mechanical* objectives for shaping and cleaning are to carve away restrictive dentine and shape the canal that is thoroughly cleaned and prepared for obturation in three dimensions. Schilder described five design objectives. They are as follows:

1. Develop a continuously tapering conical form in the root canal preparation
  - Prepare the canal in conical shape to mimic the natural shape of the canal
  - Make the canal narrower apically with the narrowest cross-sectional diameter at its terminus



**Figure 12.20** (a) The files display full curvature of the canal before *radicular* access is modified, (b) Radicular access is completed with a descending series of Gates-Glidden drills progressing towards the apex in 2.0 mm or less increments, and (c) The dotted line indicates the original curvature, whereas the file displays the affective curvature after radicular access is improved. This modification materially reduces the difficulty of apical shaping (Courtesy: JB Roane)

**Step II:** Shaping the remaining canal in a step-down approach, using a descending file sequence, progressing 1 mm per consecutive instrument, apically. It is important to recapitulate with No. 25 file to prevent blockage.

#### ADVANTAGES

- Clears bulk of the tissues and microorganisms mainly from coronal third before apical shaping
- Provides a coronal escape thereby reducing 'piston in a cylinder' effect, hence, lesser chances of apical extrusion
- Prevents binding of the instrument as coronal interferences are removed
- Straighter access to apical foramen
- Less chance of working length alteration
- Better penetration of irrigating solutions

### Crown-Down Pressureless Preparation

This technique was suggested by Marshall and Pappin (1960).

- Early coronal flaring with Gates-Glidden drills followed by an incremental removal of dentine from coronal to apical direction—hence, called 'crown-down' technique
- Straight K-files are used in a large to small sequence with a reaming motion and no apical pressure—hence, called 'pressureless' technique

After the completion of the coronal access, a provisional working length is determined and a size No. 35 file is introduced into the canal with no apically directed pressure. Then, a Gates-Glidden drill No. 2 is used short of or to the depth explored with No. 35 file. The Gates-Glidden drill No. 2 flares the coronal part, which followed by the use of Gates-Glidden drill Nos 3 and 4, sequentially, shortens the established length. The next step is the crown-down technique in which a No. 60 file is used with no apical pressure and reaming action is employed to enlarge the canal. This is followed by the use of sequentially smaller files, deeper into the canal. A radiograph is taken when an instrument penetrates the provisional working length after which apically directed procedure continues until the definitive working length is reached. The final step is to enlarge the apical area to three sizes larger than the first binding file at the working length.

### Double-Flared Technique


This technique was proposed by Fava (1983). In this technique, a small K-file is used to explore the canal following which the canal is prepared in a crown-down approach using K-files and an apical enlargement of size 30 to 40 K-file is reached. The canal is once again cleaned stepping back with descending files with frequent recapitulations using a master apical file. The canal must be irrigated



# Chapter 13

## Intracanal Medicament

V Gopikrishna and B Suresh Chandra



### INTRODUCTION

The poly microbial nature of endodontic infection contributes to the increased overall bacterial irritations that are associated with the development of certain virulent bacterial combination. The presence of certain microorganisms such as members of the black pigmented gram-negative bacteriae in root canals of teeth with necrotic pulp has been associated with increased clinical symptoms. Researchers cultured gram-positive bacteria, particularly *Enterococcus faecalis* from root canals of teeth with persistent periradicular lesions. More recently, researchers have linked symptomatic periradicular lesions to an increased prevalence of human cytomegalovirus and Epstein-Barr virus.

Disinfection of root canal is elimination of microorganisms from the pulp space within the root canal system. However, disinfection of root canal is a very important and significant phase of endodontic therapy. Successful endodontic therapy of both primary and secondary endodontic infections involves effective eradication of the causative microorganism during pulp space treatment stages. A better and favourable prognosis can be anticipated with contemporary root canal therapy where there is measures taken to effectively eradicate all kinds of microorganisms within the pulp space.

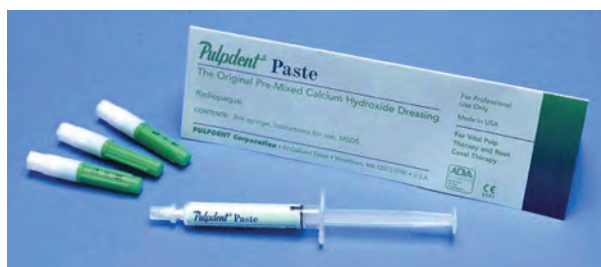For the much-accepted concept of entombment and perishment of intraradicular microbes following obturation, there is a lack of clinical documentation and scientific validity. Bacteria can exist within the root canal itself or within the other related regions such as the dentinal tubules, accessory canals, canal ramifications, apical deltas, fins, and transverse anastomoses. Pulp space anatomy is very complex. With all our hand and rotary instrumentations and irrigants, many areas of the root canal still remain inaccessible. Furthermore, it has been observed

that mechanical instrumentation with antibacterial irrigation will only render 50% to 70% of infected canals free of microorganisms depending on which regimen of irrigation is utilized. Therefore, it is believed that since there is no entirely predictable way in one treatment session to ensure complete elimination of bacteria, an effective antimicrobial agent is essential for a predetermined time period to predictably eradicate or destroy any remaining bacteria. Therefore, intracanal medicaments used as inter-appointment medicaments must be able to penetrate through the dentinal tissues in the presence of microbes to reach a sufficiently high concentration to eliminate the disease-causing bacteria in a predictable manner. Several intracanal medicaments in the form of inter-appointment medicaments have been recommended. However, five groups of antimicrobial substances have been used, which has been listed as:

1. Calcium hydroxide
2. Antibiotics
3. Non-phenols biocides
4. Phenolic biocides
5. Iodine compounds

### Microbial Flora of Pulp Space

A proper definition for endodontic pathogen should include every organism capable of inducing tissue distraction in apical periodontitis. However, majority of them refer to endodontic pathogens as the bacterium isolated from symptom-associated root canal that grows in the laboratory in a specific media. The advent of molecular genetic methods has revolutionized life sciences as a whole. It has its share of impact on microbiology in general and on oral and endodontic microbiology in particular. Possibly, one of the strongest factors contributing to the controversies often encountered in the



**Figure 13.2** Pulpdent CaOH paste.

**Table 13.2** Lethal effects of calcium hydroxide

Chemical	Physical
Damage to the microbial cytoplasm to prevent membrane by direct action of hydroxyl ions	Acting as a physical barrier ingress of bacteria
Suppression of enzyme activity and disruption of cellular metabolism	Destroying remaining bacteria by holding substrates for growth and limiting space for multiplication
Inhibition of DNA, replication by splitting DNA	

the level necessary to eliminate or kill bacteria within the dentinal tubules and anatomical variations

- Varying alkaline potential of different formulations of  $\text{Ca}(\text{OH})_2$
- Dense biofilms of bacteria located within the dentinal tubules can protect those located deeper inside the tubules
- Necrotic tissue in ramifications, isthmuses, and irregularities may protect bacteria from the action of  $\text{Ca}(\text{OH})_2$
- Ability of *E. faecalis* to colonize within the dentinal tubules, and thus, evade the hydroxyl ions
- $\text{Ca}(\text{OH})_2$  promotes the adhesion of bacteria to collagen that increases the extent of tubule invasion and thereby resistance to further disinfection

Some recent studies have revealed significant information on the effects of newer intracanal medicaments on *E. faecalis*. Chlorhexidine 2%, metronidazole, and bioactive glass have all been tried out as intracanal medicaments.

#### CLINICAL IMPLICATIONS WITH INTRACANAL MEDICAMENTS

- Always use rubber dam isolation with high-power suction
- Do not seal or use any caustic drug in the pulp space
- Look for biocompatibility clearance from authoritative bodies before selecting an intracanal medicament

- Eugenol is a periapical irritant and dispensed with a pledget of cotton wool placed in the pulp chamber only
- Use of formocresol is outdated
- Proper debridement with good irrigation regimen is the best in most clinical situations; however, weeping canals may be an exception
- Before using any antibiotic in the pulp space, be aware of its allergenic potential and hypersensitivity, and therefore, it becomes safer to prescribe a parenteral or oral dose of antibiotic following the use of an antibiotic as an intracanal medicament
- If and when an intracanal medicament is sealed in the canal take care to see that a proper intermediate access restorative is properly placed, if not anticipate a periodontal disaster
- When using  $\text{Ca}(\text{OH})_2$  as an intracanal medicament for inter-appointment dressings use only unsetting  $\text{Ca}(\text{OH})_2$
- Inter-appointment dressings have to be done with shorter durations since most intracanal medicament lose their potency in a short period of time even within 24 to 48 h of placement

#### SUMMARY

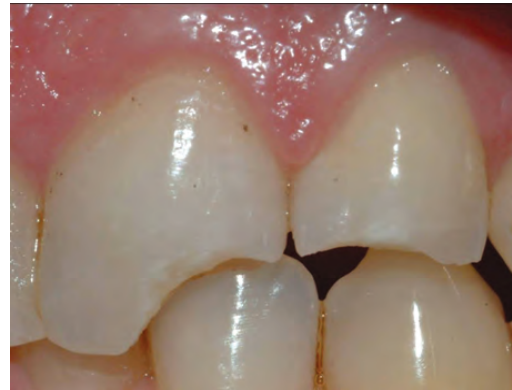Intracanal medicament is used to eliminate any bacteria remaining in the root canal after canal instrumentation especially with multiple inter-appointment dressing and in infected root canals. The choice of medicament, however, remains controversial. To justify the use, the medicament must have significantly greater antibacterial activity than its cytotoxic effect. To be effective, the medicament must be in contact with the residual bacteria in sufficient concentration. Formaldehyde and phenol type medicament have the potential to be distributed widely in the body, and in addition, formaldehyde type medicaments also have mutagenic and carcinogenic potential. Several reviews have indicated that there was little justification for the use of formocresol in dentistry.

Any antibacterial intracanal medicament must have a wide spectrum of activity and reasonable duration of activity to eliminate all the bacteria in the root canal. Since no intracanal medicament is active against the whole spectrum of root canal microbes, cocktails of antimicrobials were advocated. The first in the series was the once popular PBSC paste or PBSCN of Grossman. Generally, these pastes have not been shown to be active against the plethora of microorganisms in the root canal, and in addition, these carry the risk of allergy, sensitization, and production of resistant bacterial stains.

# Chapter 16

## Traumatic Injuries

*V Gopikrishna and L Lakshminarayanan*



### INTRODUCTION

Traumatic injuries have become more common these days and the incidences of dental traumatic injuries have also become comparatively higher. Trauma might involve both the hard and soft tissues. The injuries involve multiple structures such as the lips, cheek, tongue, floor of the mouth, bone, pulp, periodontium, dentine, cementum, and enamel. Therefore, a careful examination and diagnosis are of prime importance to manage the situation. The success of the treatment of traumatized teeth revolves around the status of the pulp and periodontium since both are vital dental structures. The reaction of pulp tissue to trauma cannot be predicted as it may recover and survive the injury, succumb immediately, or undergo progressive degeneration and ultimately die. Hence, the treatment of traumatic injuries are quite complex and at times requires a multi-disciplinary approach.

### Causes and Incidence of Tooth Injuries

1. Falls and collisions that could lead to injuries, which frequently occur in school children
2. Sporting activities could lead to injuries that are unintentional
  - frequently in teenage years
  - males sustain injuries 2–3 times more compared to females
  - maxillary incisors are more involved
3. Domestic violence could lead to injuries that could be intentional such as
  - child abuse and neglect, once called 'battered child syndrome'
  - 50% of all physical trauma occurs in head and neck region and mostly involves soft tissue injuries

4. Automobile accidents can cause
  - injuries that can encompass the entire facio-maxillary region and are not limited to tooth structure
5. Assaults
  - commonly occurs in older individuals
  - these type of injuries are closely related to alcohol abuse and injury patterns are characterized by luxation and exarticulation of teeth as well, as root fracture
  - jaw fracture

### Predisposing Factors

Factors that significantly increase susceptibility to dental injury are the following:

- Occlusal discrepancies
- Anterior over jet exceeding 4 mm
- Short upper lip
- Incompetent lips
- Mouth breathing

### CLASSIFICATION

Many classifications have been provided by different authors. Some of the important ones are listed below.

#### Ellis' Classifications (1960)

- Class I—Enamel fracture
- Class II—Dentine fracture without pulp exposure
- Class III—Crown fracture with pulp exposure
- Class IV—Root fracture
- Class V—Tooth avulsion

**Class VI**—Fracture of root with/without loss of crown structure

**Class VII**—Displacement of tooth without fracture

**Class VIII**—Fracture of crown en masse and its displacement

**Class IX**—Traumatic injuries to deciduous teeth

### Heithersay and Morile's Classification

**Class I**—the fracture line does not extend below the level of the attached gingiva

**Class II**—the fracture line extends below the level of the attached gingiva, but not below the level of alveolar crest

**Class III**—the fracture line entirely below the level of alveolar crest

**Class IV**—the fracture line is within the coronal third of root, but below the level of alveolar crest

### World Health Organization (WHO) Classification (1978)

Can be used for primary and permanent teeth and also anterior and posterior teeth.

873.60—Enamel fracture

873.61—Crown fracture involving enamel and dentine without pulp exposure

873.62—Crown fracture involving pulp

873.63—Root fracture

873.64—Crown root fracture

873.66—Luxation

873.67—Intrusion/extrusion

873.68—Avulsion

273.69—Other injuries such as soft tissue luxations

802.20;802.40—Fracture of alveolar process of mandible/maxilla

802.21;802.41—Fracture of the body of the mandible/the maxilla

### WHO'S CLASSIFICATION AS MODIFIED BY ANDERSON

873.64—Uncomplicated crown root fracture without pulp exposure

873.64—Complicated crown root fractures with pulp exposure

873.66—Subluxation

873.66—Lateral luxation

873.66—Concussion

Anderson JO and Anderson FO have given a classification to include injuries to teeth, supporting structure, gingiva, and oral mucosa.

### INJURIES TO HARD TISSUES AND PULP

- Enamel infraction
- Enamel fracture (uncomplicated crown fracture)
- Enamel dentine fracture (uncomplicated crown fracture)
- Complicated crown fracture
- Complicated crown root fracture
- Root fracture

### INJURIES TO PERIODONTAL TISSUES

- Concussion
- Subluxation
- Extrusive luxation
- Lateral luxation
- Intrusive luxation
- Avulsion

### WHO's Classification (1995)

S.02.5—Fracture of the tooth

S.02.50—Fracture of the enamel only and enamel infraction

S.02.51—Fracture of the crown of tooth without pulpal involvement

S.02.52—Fracture of the crown of tooth with pulpal involvement

S.02.53—Fracture of the root

S.02.54—Fracture of the crown with root of tooth with or without pulpal involvement.

S.02.57—Multiple fracture of tooth

### Ingle's Classification

#### Soft tissues

- Lacerations
- Contusions
- Abrasions



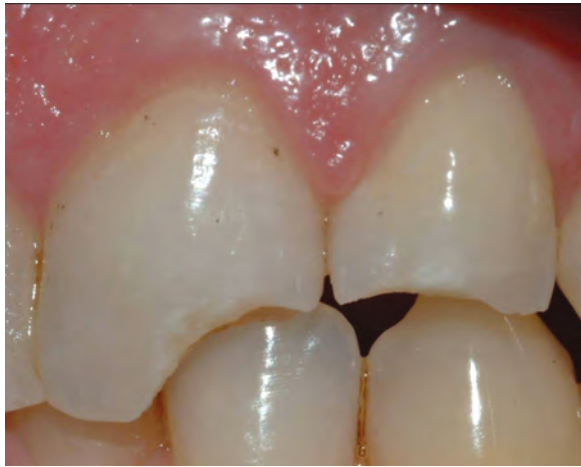
## Crown Fractures with Pulp Exposure

### CLINICAL FEATURES

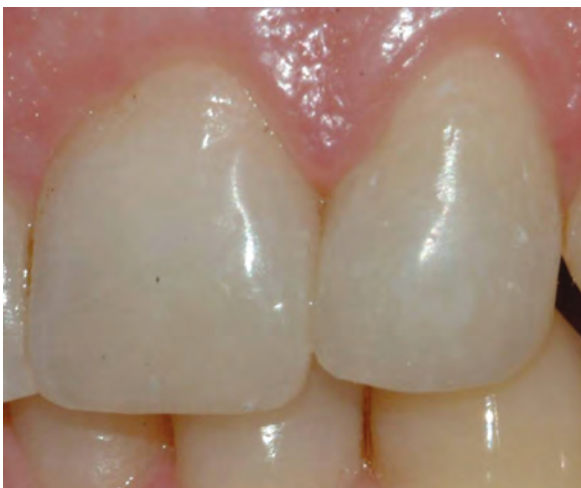- Crown fracture with pulp exposure presents clinically with a small amount of bleeding from the exposed pulp (Figs 16.3–16.5).
- The tooth may be free of symptoms or it could be sensitive to thermal change or mastication

### Treatment

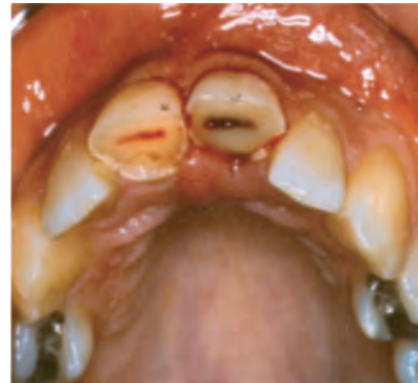The aim of treatment should be preservation of a vital, non-inflamed pulp, biologically walled off by a continuous hard tissue barrier. In most cases, this is achieved by pulp capping or pulpotomy. When these treatment alternatives



**Figure 16.3** Uncomplicated crown fracture involving dentine.



**Figure 16.4** Restored with composite restoration



**Figure 16.5** Complicated crown fracture.

are not possible, pulp must be extirpated, and root canal should be filled with adequate root canal filling material.

*In young patients with immature, still developing teeth, it is advantageous to preserve pulp vitality by pulp capping or partial pulpotomy. This treatment is also the choice in young patients with completely formed teeth. Calcium hydroxide and MTA (white) are suitable materials for such procedures. In older patients, root canal treatment can be the treatment of choice, although pulp capping or partial pulpotomy may also be selected. If too much time elapses between accident and treatment and the pulp becomes necrotic, root canal treatment is indicated to preserve the tooth. In extensive crown fractures, a decision must be made whether treatment other than extraction is feasible.*

- The presence or absence of apical closure is determined with the help of a radiograph since the treatment plan is dependent on this
- If the closure has taken place, the treatment is pulpectomy and conventional endodontic treatment
- For a tooth with open apex and vital pulp, partial pulpotomy is performed, leaving the apical portion of the pulp for completing apexogenesis. Capping the pulp is yet another method, but it is recommended only for small exposures that are treated immediately after the injury (refer Chapter 15 on pulpotomy and Apexification)

### Pulpectomy

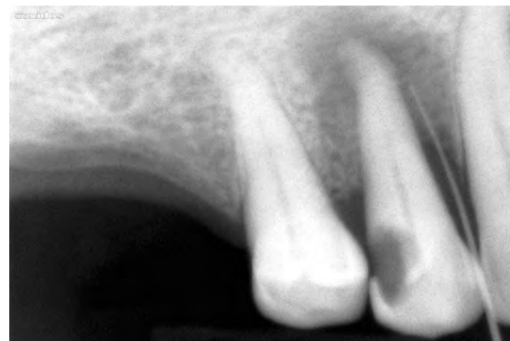It is the removal of the entire pulp to the level of 1–2 mm from the apical foramen. It is performed in matured teeth when conservative pulp treatment is not indicated. After removal of the pulp, the root canal is cleansed chemo-mechanically and obturated with gutta-percha point and suitable sealer. There are instances when interim dress-



# Chapter 18

## Endodontic Periodontal Inter-relationship

*Sunitha Raja, V Gopikrishna, and R Suresh*



### INTRODUCTION

One of the most complex conditions to treat and also one of the most widely studied inter-disciplinary fields in dentistry is the pulpo-periodontal inter-relationship. The tooth, the pulp tissue within it, and its supporting structures should be viewed as one biologic unit. The periodontium and the pulp have embryological, developmental, anatomical, histological, and clinical relationship. Periodontal therapy deals with the prevention and repair of the lesions of the supporting structures. Endodontics deals primarily with the treatment of the diseases of the pulp and the periapical tissues. However, both pulpal and periodontal diseases have their terminal effects in the periodontal tissues, namely, cementum, periodontal ligament, and alveolar bone. The success of both periodontal and endodontic therapy depends on the elimination of both disease processes, whether they exist separately or as a combined lesion.

Important minor structures maintain communication between the periodontium and the root canal system, which makes it possible for the disease process in one to influence the other. With such influences in the spread of infection and inflammation, the symptoms overlap so much that it would be very challenging to diagnose the condition and perform the necessary treatment. This necessitates combined therapy most of the times. The effect of pulp on the periodontium is not only on the inflammatory process but also on its healing process. An overview about pulpo periodontal pathology, their communications, diagnosis, classification, and treatment is given in this chapter.

### RELATIONSHIP OF PULP AND PERIODONTIUM: DEVELOPMENTAL ASPECTS

Developmentally, except for enamel, which is an ectodermal derivative, all the other dental structures are formed by neural crest cells that later condense in developing maxilla and mandible as dental papilla and dental follicle, the former giving rise to pulp and the latter to periodontal structures.

During root formation, the outer and inner enamel epithelium join together to form Hertwig's epithelial root sheath. The epithelial root sheath elongates to form the root. When epithelial root sheath breaks down before root formation accessory and lateral canals form. During development, many of the anastomoses are blocked or reduced by the formation of dentine or by deposition of cementum. Sometimes anastomoses between dental papilla and dental sac may persist.

Some of the communications between the pulp and periodontium may remain patent in the adult dentition. The communication of the vessels of the pulp and periodontium are one such important aspect. The branches of the alveolar arteries supply both the tooth and its supporting structures, making the blood supply of both these structures common. Besides this, there is also an extensive communication between the periodontal vessels and the pulp through the apical/accessory foramen.

**Primary periodontal lesion:** Local factors such as plaque and calculus initiate gingivitis, which when left untreated can lead to destruction of bone, periodontal ligament, and cementum (Fig. 18.2a). The epithelial attachment migrates apically converting a healthy sulcus into a pocket. The pocket deepens, bone loss continues, and the ligament space widens (Fig. 18.2b). Vitality of the tooth is maintained. Hence, increased probing depth, widespread lesion, generalized involvement, mobility, furcation involvement, purulent discharge with positive vitality test confirms a primary periodontal lesion. Exclusive periodontal treatment strengthens the prognosis of the tooth.

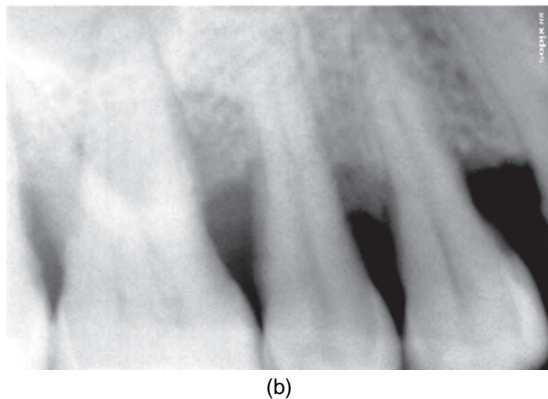
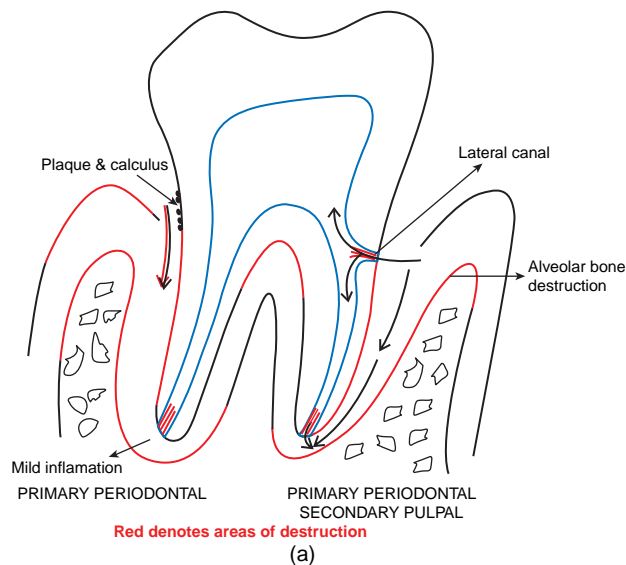
**Primary endodontic with secondary periodontal involvement:** The endodontic lesion left untreated

progresses into a chronic stage with the destruction of periodontal tissues into the level of the gingival sulcus. Simultaneously, accumulation of plaque and calculus in the deepened sulcus (pocket) leads to an apical shift of the epithelial attachment (Fig. 18.1). There is radiographic evidence of periapical pathology and angular (or triangulation) bone loss (Fig. 18.3).

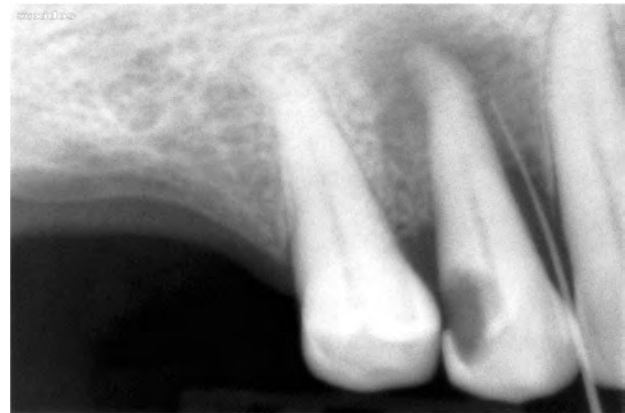Primary endodontic lesion with secondary periodontal involvement can also occur in case of root perforations during endodontic treatment or where pins and posts have been misplaced during restoration of the crown. Symptoms can vary from an acute state with abscess formation, associated with swelling, pain, mobility, exudates, and pocket formation to a chronic state with no symptoms and a sudden appearance of a pocket with bleeding on probing.

Root fractures may also present as primary endodontic lesions with secondary periodontal involvement. This occurs typically in root canal treated teeth, often restored with posts and crowns. Vitality testing is mandatory in all cases. For this type of lesion, both endodontic and periodontal therapy is required and prognosis is slightly compromised compared to primary endodontic lesion only.

**Primary periodontal secondary endodontic lesion:** Earlier we have seen that the influence of periodontal disease on the pulp is through dentinal tubules, lateral/accessory canals, and the apical foramen. Mild periodontitis when not treated can progress to advanced periodontitis. Apical progression of the periodontal pocket may continue until the apical tissues are involved. The pulp may become necrotic. However, if the blood supply circulating through the apex is intact, the pulp has good prospects for survival.



**Figure 18.2** (a) Left portion of the figure depicts a primary periodontal lesion. Right portion depicts a primary periodontal lesion with secondary endodontic involvement (Courtesy: Sathyanarayanan.) and (b) Primary periodontal lesion—Radiograph reveals bone loss and furcation involvement.

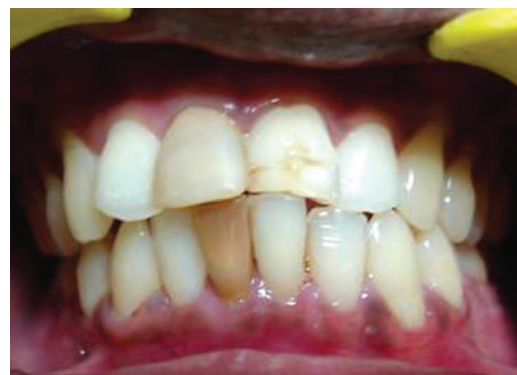

**Figure 18.3** Primary endodontic with secondary periodontal.

# Chapter 20

## Management of Discoloured Teeth

*Krithika Datta and V Gopikrishna*



### INTRODUCTION

The face of modern dentistry is interpreted by the general population as a means to improve facial appearance and dental aesthetics. On an average, people relate improved aesthetics to a brighter and whiter smile. A lighter dentition is associated with vigour, youth, and health. This change in perception of aesthetics urges people to opt for tooth-whitening procedures.

### CLASSIFICATION OF TOOTH DISCOLOURATION

Newly formed enamel is thick and has a smooth surface. This translucent enamel modifies the colour of the underlying dentine, resulting in a milky white appearance. The surface and structure of the enamel and dentine can get modified due to various reasons, which result in modification or discolouration of the tooth colour. Tooth discolouration can be broadly classified as those occurring due to discolouration of dentine due to structural alterations or penetration of the tooth structure by discolouring agents. It can be defined as intrinsic or extrinsic. Intrinsic changes are the structural changes on the enamel surface; and extrinsic changes are the superficial changes on the enamel surface. Incorporation of extrinsic stain into the tooth structure following dental development is internalized discolouration.

#### Intrinsic Discolouration

Intrinsic discolouration occurs following a change to the structural composition or to the thickness of the dental

hard tissues. A number of metabolic diseases and systemic factors are known to affect the developing dentition and cause discolouration as a consequence. Local factors, such as injury, are also recognized as factors that can cause intrinsic discolouration.

1. Alkaptonuria
2. Congenital erythropoietic porphyria
3. Congenital hyperbilirubinaemia
4. Amelogenesis imperfecta
5. Dentinogenesis imperfecta
6. Tetracycline staining
7. Fluorosis
8. Enamel hypoplasia
9. Pulpal haemorrhagic products
10. Root resorption
11. Ageing

#### Extrinsic Discolouration

Extrinsic discolouration is outside the tooth substance and lies on the tooth surface or in the acquired pellicle. The origin of the stain may be due to any of the following:

1. Metallic
  - Occupational exposure to metallic salts
  - Medicines containing metal salts
2. Non-metallic
  - Dietary components
  - Beverages
  - Tobacco
    - a. Mouthrinses
    - b. Medicaments
    - c. Chromogenic bacteria

Nathoo (1997) has developed three classifications of extrinsic discolouration:

1. **N1 type dental stain or direct dental stain:** The coloured materials (chromogen) bind to the tooth surface and cause discolouration. The colour of the dental stain is same as the colour of the chromogen
2. **N2 type dental stain or direct dental stain:** The chromogen changes colour after binding to the tooth
3. **N3 type dental stain or indirect stain:** Colourless material or a prechromogen binds to the tooth and undergoes chemical reaction to cause a stain

### Internalized Discolouration

Internalized discolouration is the incorporation of extrinsic stain within the tooth substance following dental development. It occurs in enamel defects and in the porous surface of exposed dentine. The routes through which pigments may become internalized are the following:

1. Developmental defects
2. Acquired defects
  - a. Tooth wear and gingival recession
  - b. Dental caries
  - c. Restorative materials

The causes and colours of tooth discolouration are given in Table 20.1.

## MECHANISM OF TOOTH DISCOLOURATION

### Intrinsic Discolouration

This occurs during tooth development that results in an alteration in the light transmitting properties of the tooth structure.

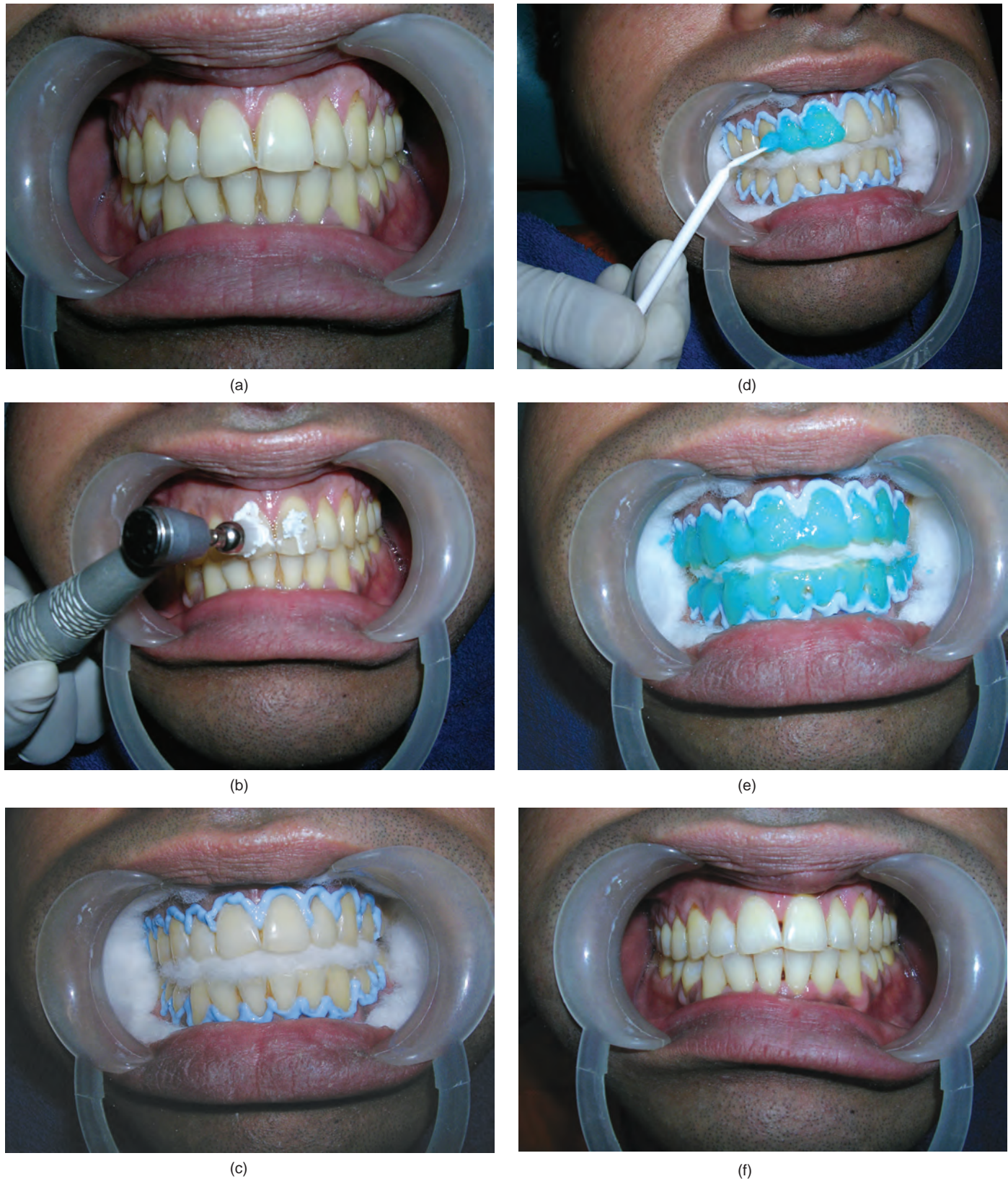1. **Alkaptonuria:** This affects the permanent dentition by a brownish discolouration. This occurs due to an inborn error in the metabolism of tyrosine and phenylalanine that results in the accumulation of homogentisic acid
2. **Congenital erythropoietic porphyria:** This is an autosomal recessive disorder affecting the metabolism of porphyrins. Porphyrins are accumulated into the bone marrow, red blood cells, and teeth
3. **Congenital hyperbilirubinaemia:** The breakdown products of haemolysis cause yellow-green discolouration of teeth. It is seen in cases of neonatal jaundice and more severe in cases of Rh incompatibility (*Erythroblastosis fetalis*)

**Table 20.1** Causes and colours of tooth discolouration (Abbott PV. 'Aesthetic considerations in endodontics: Internal bleaching'. Pract Pract Periodontics Aesthet Dent 9(7): 833-40, 1997.)

Cause	Colour
<b>Extrinsic discolouration</b>	
Cigarettes, pipes, cigars, chewing tobacco, etc	Yellow-brown to black
Marijuana	Dark brown to black rings
Coffee, tea, foods	Brown to black
Poor oral hygiene	Yellow or brown shades
<b>Extrinsic and intrinsic discolouration</b>	
Fluorosis	White, yellow, brown, grey, or black
Ageing	Yellow
<b>Intrinsic discolouration</b>	
Genetic condition,	
e.g. amelogenesis imperfecta	Brown, black
dentinogenesis imperfecta	Brown, blue
Systemic conditions,	
e.g. jaundice	Blue-green or brown purple
porphyria	brown
Medications during tooth development,	
e.g. tetracycline, fluoride	
Body by-products,	
e.g. bilirubin	Brown, grey, or black
haemoglobin	Blue-green, brown
Pulp changes,	
e.g. pulp canal obliteration	Grey, black
pulp necrosis	Yellow
-with haemorrhage	
-without haemorrhage	Grey, black yellow, grey-brown
<b>Iatrogenic causes</b>	
e.g. trauma during pulp extirpation	Grey, black
tissue remnants in pulp chamber	Brown, grey, black
restorative dental materials	Brown, grey, black
endodontic materials	Grey, black

4. **Amelogenesis imperfecta:** This hereditary condition has diverse manifestation depending on the stage at which the ameloblasts are affected during enamel formation. Defective matrix formation results in shearing

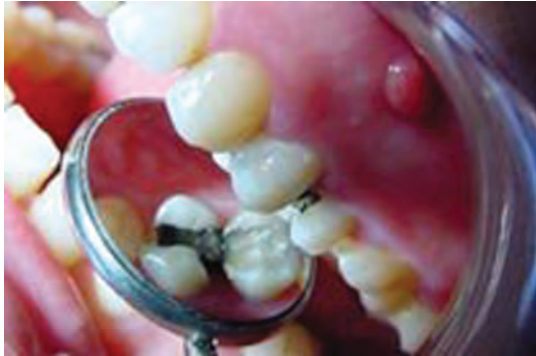



**Figure 20.9** In-office vital bleaching: (a) Preoperative photograph, (b) Pumice prophylaxis, (c) Isolation and liquid dam application, (d) Application of 33% carbamide peroxide, (e) Bleaching action for 8-10 min, and (f) Postoperative. (Courtesy: Dr Archana Narayanasamy, Rajan Dental Institute, Chennai.)



# Chapter 21



## Endodontic Emergencies

*Anil Kohli and V Gopikrishna*

### INTRODUCTION

Endodontic emergency is defined as a condition associated with pain and/or swelling that requires immediate diagnosis and treatment. In most of the endodontic emergency cases, the cause is severe pain; sometimes swelling may also be present. Pain can originate from the pulp or the periapical area. Severe pain mostly originates from the pulp. Endodontic emergencies are the results of combinations of various factors that induce severe inflammation in the pulp and periradicular tissues. The pain in endodontic emergencies is mainly related to two factors, namely, chemical mediators and pressure. Chemical mediators cause pain directly by lowering the pain threshold of sensory nerve fibres or by increasing vascular permeability and producing oedema. Increased fluid pressure resulting from oedema directly stimulates the pain receptors.

### CLASSIFICATION

Endodontic emergencies are categorized into three main types. They are the following:

1. Before treatment
  - Acute pulpitis
    - Acute reversible pulpitis
    - Acute irreversible pulpitis
  - Acute abscess
    - Alveolar abscess
    - Periodontal abscess
  - Acute pulpitis with apical periodontitis
  - Traumatic injury

2. During treatment
  - Hot tooth
  - Inter-appointment flare ups
3. After treatment
  - Postendodontic pain
  - Vertical root fracture

### BEFORE TREATMENT

#### Acute Reversible Pulpitis

##### DIAGNOSIS

The origin of the condition can be confirmed by visual, tactile, and thermal examination of the isolated tooth. In reversible pulpitis, the pain is immediately relieved as soon as the stimulus is removed. Tooth is usually not tender to percussion, unless the cause is the recently done high filling.

##### CAUSES

- Recent high restoration
- Fractured cement base
- Broken filling
- Marginal leakage
- Heat produced during cavity cutting procedures or chemical cleansing of the cavity
- Secondary caries

##### MANAGEMENT

- Removal of the cause
- Apply pulp-protective base under all restorations
- Avoid marginal leakage
- Relieve the occlusion if present
- Avoid injuring the pulp with excessive heat during preparation or polishing a metallic restoration

## Treatment

Most of the times there is some discomfort following obturation that subsides in 2–5 days. On radiographic examination, it is observed that the area of rarefaction has not healed or radiolucency persists around the root tip. This may be either due to improper canal debridement or due to lateral or accessory canals. If possible, remove the filling and repeat the treatment involving complete root canal system.

## Vertical Root Fracture

### AETIOLOGY

- During obturation, the wedging effect of a spreader or plugger leads to fracture
- Structurally, weakened-root treated teeth that have been restored with a short wide tapered post
- The chances of root fracture are increased if the coronal restoration fails to provide a ferrule effect on the remaining root structure

Pain during mastication is the most common symptom.

### DIAGNOSIS

- In severe cases, a root fracture may be visible radiographically; the presence of a lateral diffuse widening of the periodontal ligament is the characteristic radiographic appearance
- Periodontal probing may locate an isolated, narrow pocket adjacent to the fracture site
- Full thickness of the muco-periosteal flap should be reflected. To corroborate the diagnosis, the root should then be stained and viewed under magnification

### MANAGEMENT

The prognosis for a vertical root fracture extending apically from the alveolar crest is poor, and tooth extraction is often indicated.

### Antibiotics

Flemming produced the first antibiotic over 60 years ago. Antibiotic will attack cell structure and metabolic paths, unique to bacteria and not shared with human cells. Antibiotics are substances that are produced by microorganisms to suppress or to kill other microorganisms at very low concentration. These drugs attack cell structure and metabolic pathways of bacteria, but not the human cells.

## Classification

1. Based on spectrum of activity
  - Narrow spectrum
    - Penicillin G
    - Streptomycin
    - Erythromycin
  - Broad spectrum
    - Tetracyclines
    - Chloramphenicol
2. Type of action
  - Bactericidal
    - Penicillin and cephalosporins
    - Metronidazole
    - Fluroquinolone
    - Aminoglycosides
  - Primarily bacteriostatic
    - Sulphonamides
    - Tetracycline
    - Clindamycin
    - Erythromycin
3. On the basis of family
  - Penicillins
  - Cephalosporins
  - Sulphonamides
  - Tetracyclines
  - Aminoglycosides
  - Macrolides

The recommended standard regimen for dental procedures is penicillin V, 2.0 gm orally 1 h before the procedure, then 1.0 gm 6 h later. Erythromycin may be prescribed as given, 1.0 gm orally 1 h before, then 500 mg 6 h later in case if the patient is allergic to penicillin. Penicillin should not be prescribed for a patient with a history or suspicion of penicillin allergy. Erythromycin's mode of action is inhibition of protein synthesis; however, its antibacterial spectrum is similar to that of penicillin. Resistant forms can occur and have been reported for staphylococci, streptococci, and enterococci. As erythromycin is acid labile, it should be taken with food. It can be administered in tablets having an acid-insoluble coating to ensure effective blood levels and to prevent inactivation by stomach acid.

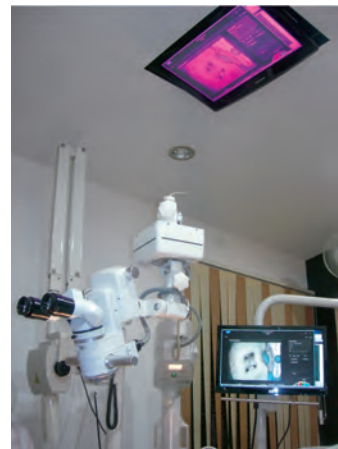### Tetracycline

It will inhibit bacterial protein synthesis and is bacteriostatic in nature. It is a broad-spectrum antibiotic, which is effective against gram-positive and gram-negative organisms. Absorption of tetracycline is inhibited by chelation with milk.

# Chapter 24

## Microscopes in Endodontics

V Gopikrishna and Anil Kohli



### INTRODUCTION

Success of root canal therapy lies in the magnification, location of all the canals, its subsequent cleaning and shaping, and three-dimensional obturation.

Performing endodontic therapy is like working inside a blind space wherein procedures are done by tactile sensation and presumptions. Time over, radiographs have been the helping hand to see the quality of work done inside the root canal. In addition to it, surgical loupes and telescopes were also used in conventional endodontics.

The introduction of dental operating microscopes has revolutionized a new era in endodontics. Microscopes are useful in diagnosis, locating extra or missed canals, locating the MB2 canals, removing separated instruments, and prevent and manage mishaps. Every challenge that exists up to the curvature in the root can be easily visualized. Re-treatment of endodontic failures has become easier and more predictable, thereby increasing the success rate.

The operating microscope and the ultrasonic instruments have taken endodontic surgery to another level of sophistication, the *microsurgical approach*. Magnification, illumination, and instruments constitute a *microsurgery triad*. Apical surgery can now be done with more accuracy and predictability eliminating the guess factor inherent in conventional endodontics.

### HISTORY

The use of microscopes first began in the fields of ophthalmology, neurosurgery, and otolaryngology. Before microscopes gained popularity in dentistry, usage of loupes and telescopes seemed adequate. Surgical loupes and telescopes provide a magnification of 2.0× to 4.0×.

Operating microscopes were introduced into dentistry in 1982. By 1995, there was an obvious increase in the use of microscopes amongst endodontists.

### Parts of a Microscope

The head of the microscope has three main parts (Fig. 24.1):

1. An eyepiece lens
2. Body tube optics
3. An objective lens

The operator views the field through the eyepiece lens. Both the eyepiece and the objective lens have convex lenses. It is essential to understand some physics terminologies before going into further details of a microscope.



Figure 24.1 Head of a microscope.

### PRINCIPAL FOCUS

When rays parallel to the principal axis pass through a lens, they converge to a point F on the principal axis called the principal focus of the lens.

## How the Dental Operating Microscope Works

To appreciate what a surgical operating microscope can do, it is essential to understand how it works

- Magnification
- Illumination
- Documentation
- Accessories

### MAGNIFICATION

Magnification is determined by the power of the eyepiece, the focal length of the binoculars, the magnification changer factor, and the focal length of the objective lens. *Eyepieces* are generally available in various powers of 6.3×, 10×, 12.5×, 16×, and 20× (Fig. 24.5).

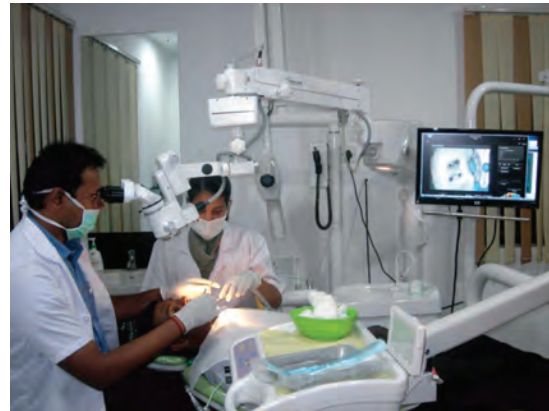### Binoculars

The function of binoculars is to hold the eyepieces. As in a typical pair of field binoculars, the inter-pupillary distance is set by adjusting the distance between the binocular tubes. Binoculars often come in different focal lengths. In choosing binocular focal lengths, it is important to remember that the longer the focal length the greater the magnification and the narrower the field of view (Fig. 24.6). Shorter length binoculars allow the operator to have a wider field of view and to be little closer to the patient. Binoculars are available with straight, inclined, or inclinable tubes.

- **Straight tube binoculars** are so oriented that the tubes are parallel to the head of the microscope. They are suggested to be so because they allow the operator to look through the microscope directly at the operating field
- **Inclined binoculars** are so oriented that the tubes are offset at 45° angle to the head of the microscope. They could be used for maxillary surgery, but the operator would have to use indirect vision through a mirror so positioned that the patient's head is viewable sharply to the side, while performing mandibular surgery



**Figure 24.5** Eyepiece.



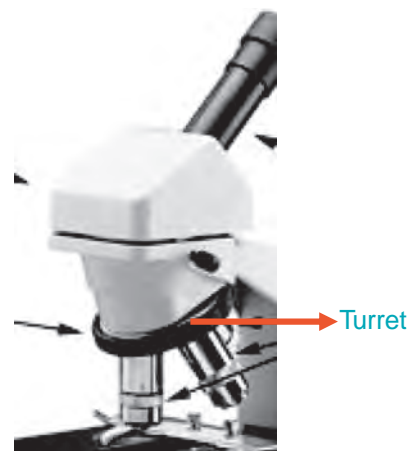
**Figure 24.6** Operator on a dental microscope.

- **Inclinable tubes** are adjustable between the straight tube and slightly beyond the inclined tube positions up to and sometimes beyond 90°. They can often provide the operator with additional postural comfort during long procedures. The only disadvantage is that they are difficult to engineer and can be quite expensive

### Magnification Changers

Magnification changers are located within the head of the microscope. Magnification changers are available as either three- or five-step manual changers (Fig. 24.7). Manual step changers consist of lenses that are mounted on a turret.

A conventional three-step changer has one set of lenses and blank space on the turret and are factored in three fixed powers of magnification, two from each lens pair combination and one from the blank space. A five-step manual changer has a second set of lenses mounted on the turret and produces five fixed powers of magnification.



**Figure 24.7** Manual magnification changer.



# TEXTBOOK *of* ENDODONTICS

**Textbook of Endodontics** is a comprehensive text on current practice, trends and philosophy in the art and science of endodontics. The book has been specifically written keeping the curriculum needs of a final year undergraduate student in mind, and is strictly as per the Dental Council of India (DCI) guidelines.

## Salient Features

- Covers basic concepts and techniques of endodontics exhaustively
- Includes chapters on **Microbiology in Endodontics, Isolation and Infection Control in Endodontics, Pathobiology of Apical Periodontitis, Obturation of Root Canal System, Pulpotomy and Apexification, Endodontic Microsurgery, Endodontic Emergencies, Lasers in Endodontics, Microscopes in Endodontics** and many more
- Truly international standard textbook with the right blend of national and international contributors
- International contributors' list includes top 5 academicians, who have already contributed in well-established books like *Pathways of the Pulp* (Cohen), *Textbook of Endodontics* (Ingle), etc.
- Chapter on **"Problem Solving in Endodontic Access Openings, Cleaning, Shaping, and Root Canal Obturation"** contributed by **James L Gutmann**, author of the famous book *Problem Solving in Endodontics*
- Includes more than 600 original colour photographs, radiographs, histologic slides, flowcharts and line illustrations
- Provides numerous case reports for better understanding of the clinical procedures
- A must for Undergraduate dental students but also useful for Postgraduate students and general practitioners



**Anil Kohli** completed his graduation and postgraduation from Faculty of Dental Sciences, King George's Medical College, Lucknow. He is widely respected for his immense contributions to the field of Dentistry all over the world. In appreciation of his distinguished services, he was conferred the 'Padma Shree' in 1992 and the 'Padma Bhushan' in 2005. He has also received the coveted 'Dr B C Roy National Award' as well as the 'S S Bhatnagar Award' from King George's Medical College, Lucknow, for his outstanding work.

Dr Kohli has published several research papers in National and International journals, headed several professional bodies and is currently the President of Dental Council of India. In recognition of his outstanding contributions, he has been conferred the Honorary rank of 'Brigadier' in the Army Dental Corps. He is also Dean, Faculty of Dentistry, Baba Farid University, Punjab. He is an Adjunct Professor to Boston and Tufts University. He has been awarded fellowship of Royal College of Dental Surgeons of England. He is the Chairman of Education Committee, Asia Pacific Dental Congress (APDC) and a member of the Education Committee of Fédération Dentaire Internationale (FDI). He has to his credit 10 honorary PhD / DSc degrees from various national and international universities.

ELSEVIER

*A division of*

Reed Elsevier India Pvt. Ltd.

ISBN 978-81-312-2181-5



9 788131 221815